Pathology of the breast

Dr Tim Bracey
Histopathology SpR

Structure of tutorial

- Predominantly breast cancer
- Anatomy of breast
- Types of lumps in breast
- Features of benign and malignant lumps
- Clinical assessment, symptoms and signs
- Genetic and hormonal factors
- "Carcinoma in situ" and carcinomas
- Aetiology, risk factors and epidemiology
- Staging and management

What is the structure of the breast?

Name 5 types of benign breast lump that may be confused with cancer

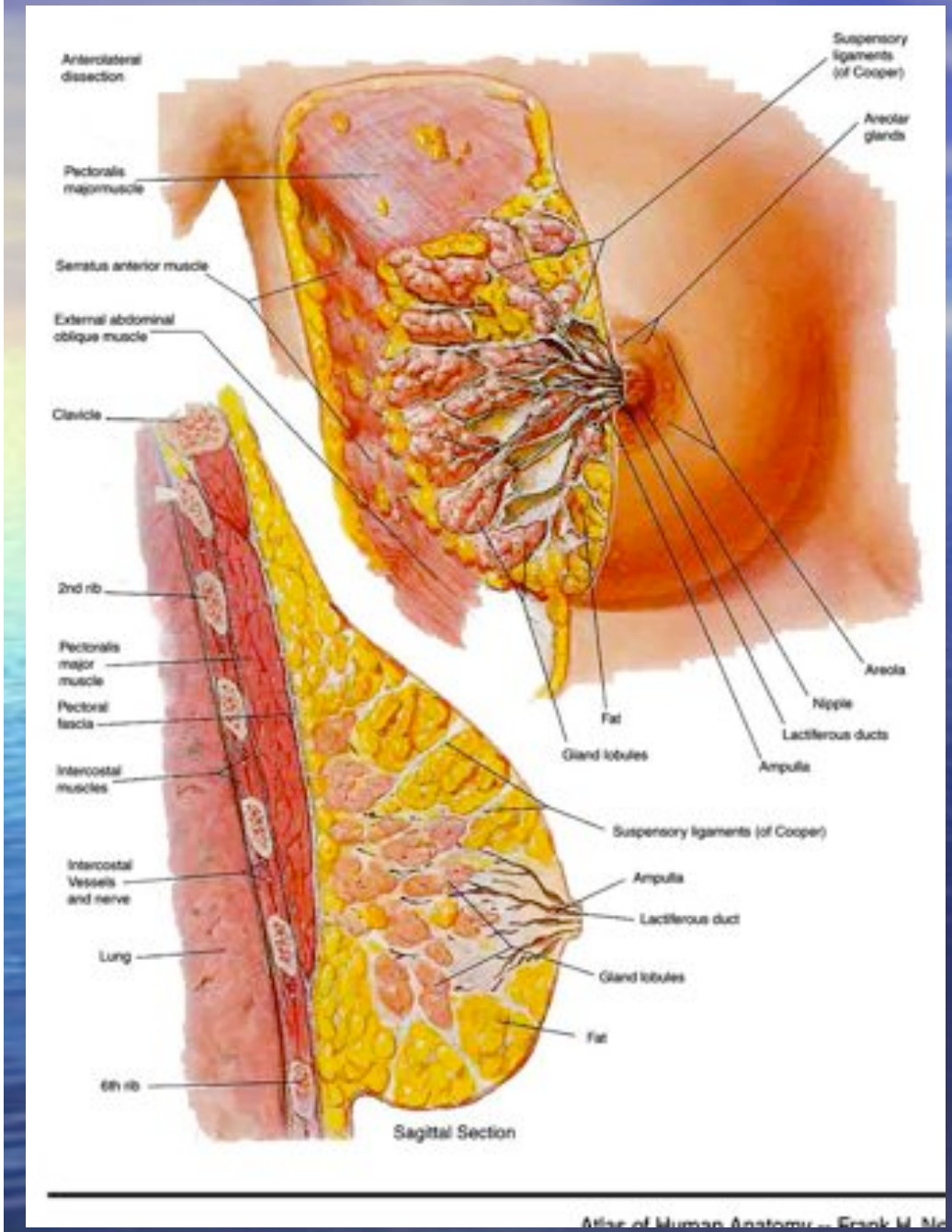

- Paired glands between 2nd and 6th ribs
- Covered with skin
- Lie on the pec major muscle between two fascial layers which are connected by suspensory ligaments (of Cooper)
- Hierarchical structure, alveoli, lobules, lobes, ducts, sinuses, nipple
- Glands and stroma surrounded by fat
- Blood from subclavian
- Lymph drainage to axilla (97%) and int mammary

95% of breast lumps are either:

- Carcinoma of the breast
- Cyst
- Fibroadenosis (fibro-cystic disease)
- Fibroadenoma

Other breast lumps

- Skin lumps (benign and malignant)
- Thrombosis of the superficial veins of the breast or chest wall (Mondor's disease)
- Lipoma
- Abscess
- Fat necrosis
- Duct papilloma
- Sarcoma (rare)
- TB, rib tumour

Fibroadenoma

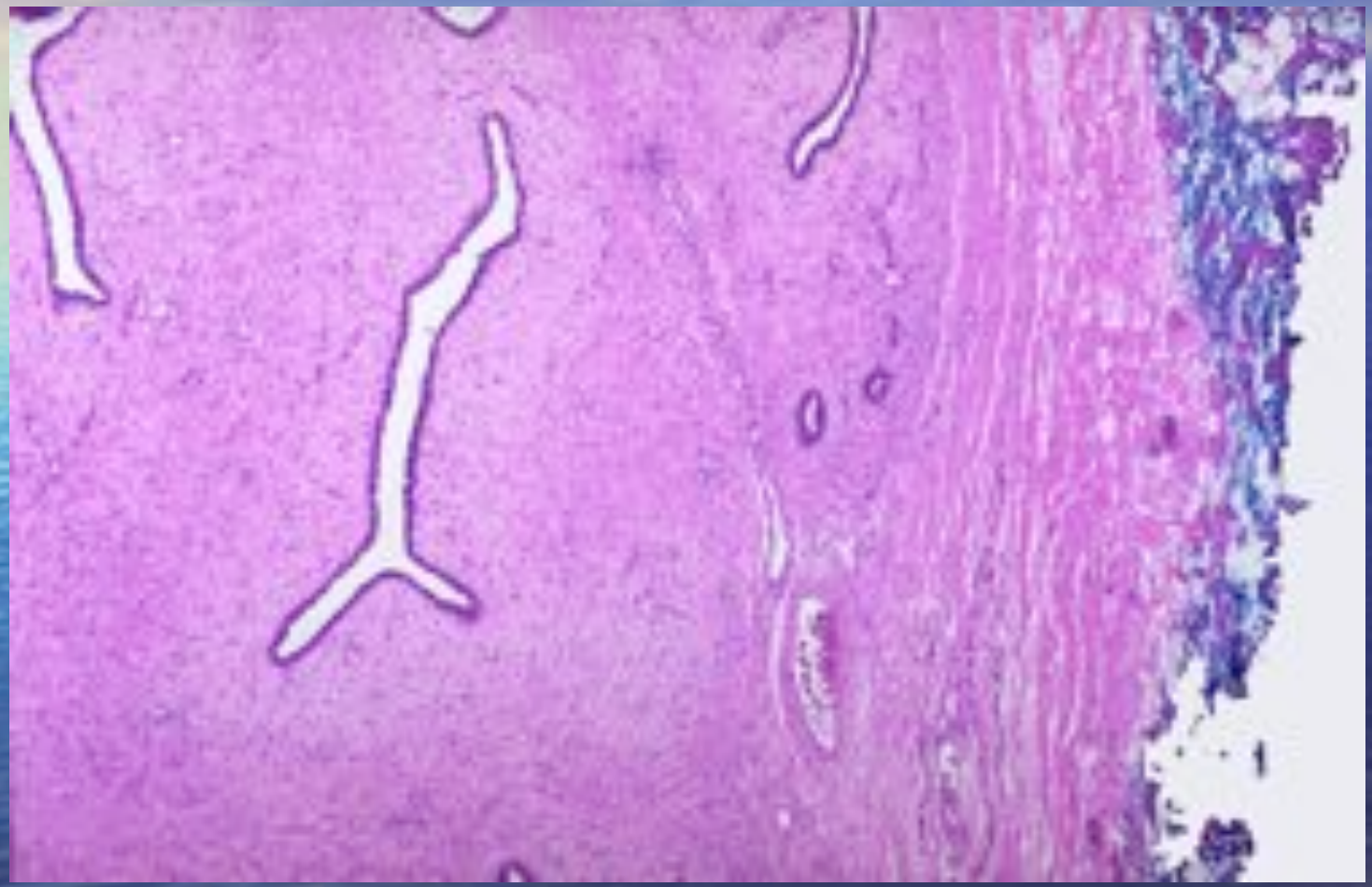

Fat necrosis

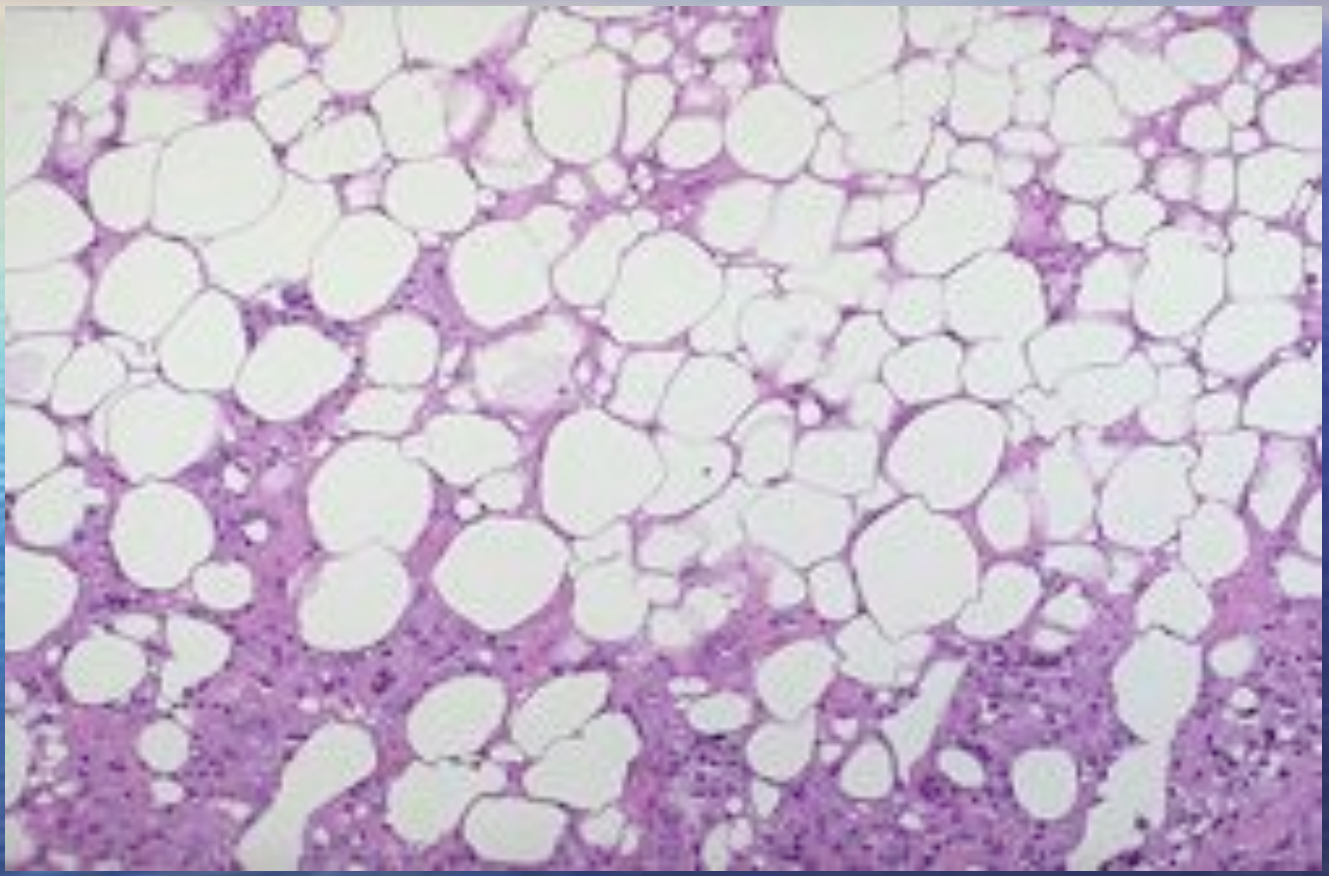

Implant rupture

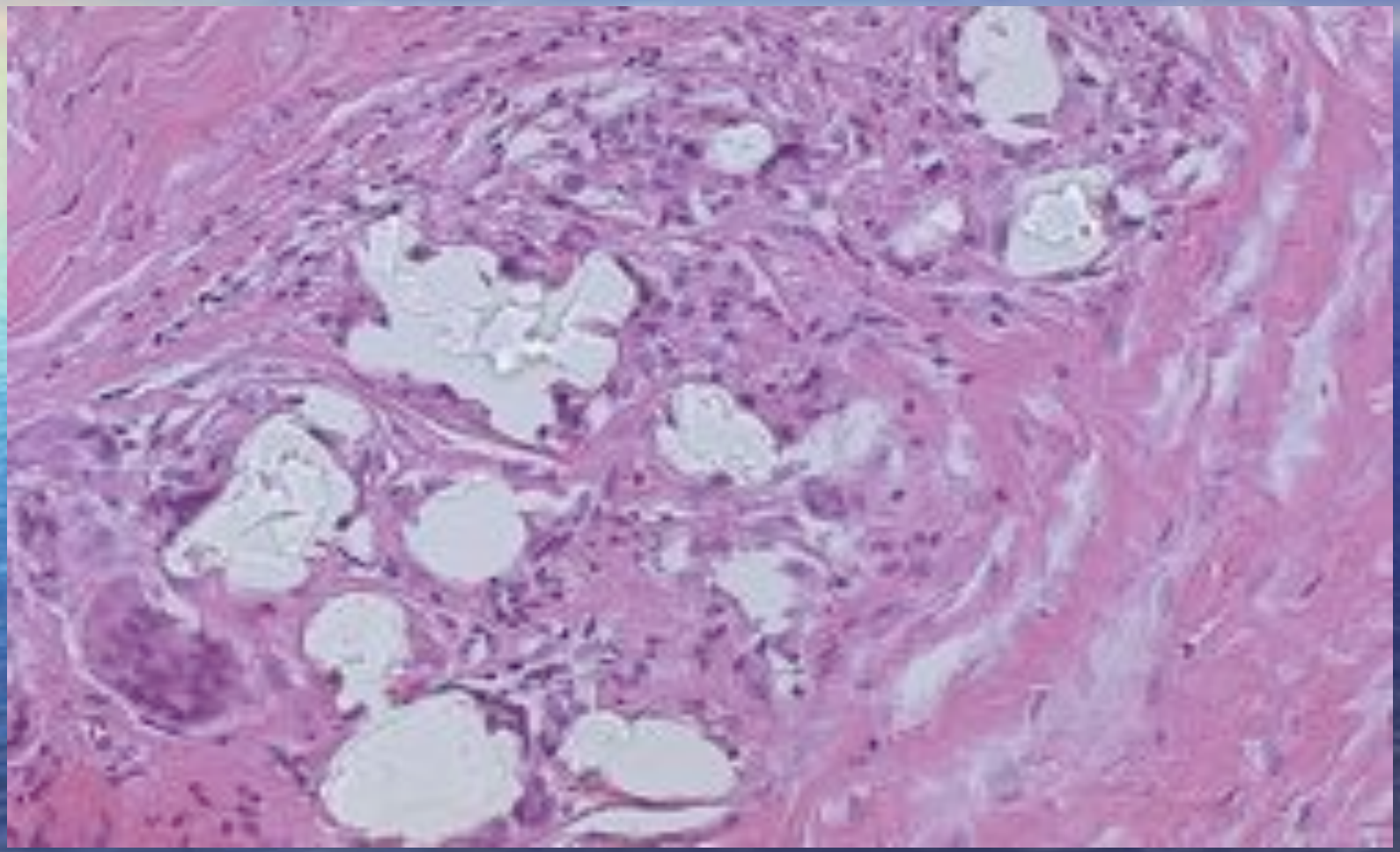

Name 3 features of benign lumps and 3 characteristics of malignant lumps

Name 5 clinical signs on examination related to breast cancer (other than a lump)

Clinical History

- Duration Sx, presentation, pain etc.
- Previous breast disease or breast trauma
- Menarche / menopause
- Parity, breast-feeding.
- Medications (OCP, HRT)
- Family history

Clinical Examination

- Chaperone
- Inspection of breasts
- Patient sitting up, fully exposed

Clinical examination

- Any previous mastectomy scars, Bx sites.
- Nipple tethering/retraction/inversion/ discharge.
- Peau d'orange, skin reddening.
- Paget's disease of the nipple.
- ?? ulceration.
- And usual, signs of metastatic disease

Clinical examination

If a mass is felt note:

- Site, size, shape, surface, surroundings
- Consistency, ?transillumination
- Tenderness
- Fixation, tethering, mobility
- Single or multiple lesions

Benign - painful, smooth, regular, no skin dimpling or nipple retraction, cyclical changes

Malignant - painless, hard/irregular/fixed

Clinical Examination

- When examining axilla, support the weight of the ipsilateral arm
- All four quadrants + axillary tail
- Is there matting of LNs?

Clinical Examination (4)

- Don’t forget to examine the liver.

- As well as the other major systems.

Nipple retraction

Dimpling/Tethering

Peau d’Orange

Paget's disease of the nipple

Almost invariably sign of underlying invasive cancer or DCIS

Paget's disease of the nipple

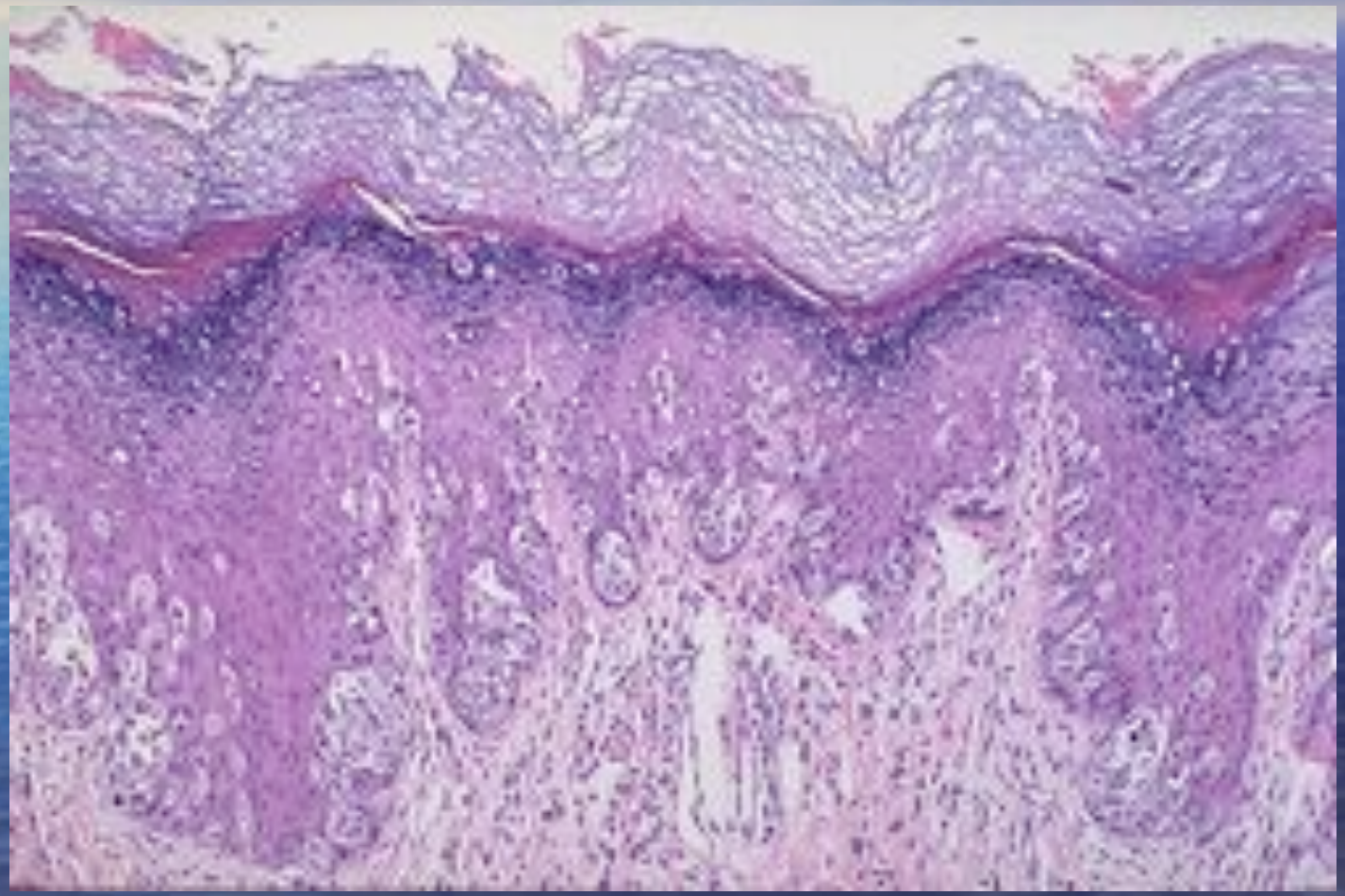

Nipple discharge (1)

- 1. Blood-stained:
  - Duct papilloma
  - Intraduct carcinoma (DCIS)
  - Paget's disease
  - Invasive carcinoma (unusual)

Nipple discharge (2):

- 2. Serous: early pregnancy
- 3. Yellowish, brown, green: fibroadenosis (duct ectasia)
- 4. Milky:

  galactorrhoea after lactation,

  also hyperprolactinaemia

  (e.g. from pituitary adenoma/drugs)
- 5. Purulent: breast abscess

What happens at the one-stop breast clinic?

How are asymptomatic lesions picked up?

Triple assessment

- Clinical examination - lump and regional nodes
- Imaging (ultrasound <35 yrs, mammogram >35 yrs)
- FNA or biopsy
  - C1=inadequate
  - C2=definitely benign
  - C3=probably benign
  - C4=probably malignant
  - C5=definitely malignant

Screening

- Started in 1989
- 50-69 year olds invited for mammogram every 3 years
- If abnormal, further assessment by FNAC or core biopsy
- Common exam question - Wilson criteria for a screening test

Name 5 factors known to increase risk of developing breast cancer (excluding genetics)

Name 3 factors with a protective effect against developing breast cancer

Breast Carcinoma

- Britain has highest breast cancer mortality
- Increasing in incidence.
- Uncommon in <30s.
- Disease of 'Western world'

  (Incidence higher in N America / Europe vs Asia and Africa)

Breast carcinoma: risk factors

- Advanced age
- Born in N Europe or N America (esp if white and high social class)
- Previous breast/endometrial/ovarian carcinoma
- Pre-existing proliferative disease
- Chest wall irradiation
- Family history (any first degree relative)
- Early menarche, late menopause.
- Nulliparity
- First child over 30
- Postmenopausal obesity
- High unsat fat diet, physical inactivity

Breast carcinoma: protective factors

- Age at first period >15 years
- Breastfeeding more than 1 year
- Unsaturated fat rich diet
- Physical activity

Pathogenesis

- Genetic mutations
- Hormonal influences
- Enivronmental influences

Name 3 genetic factors or inherited syndromes conferring an increased risk of breast cancer

Genetic factors

- As with all cancers, breast ca is the result of multiple genetic changes or mutations
- Hereditary breast cancers represent a small proportion (around 10%)
- Mutations in BRCA1 and BRCA2 responsible for ~ 40% inherited cases
- BRCA1 ~80% risk at 80 yrs
- BRCA2 25-30% breast ca risk in female carriers, also increased risk of male breast ca and other cancer types
- Li Fraumeni syndrome
- Cowden disease, Peutz-Jehgers, Muir-Torre

Name 3 cellular mechanisms involved in breast carcinogenesis

What is the clinical significance of HER2 and c-erbB2?

Mechanisms of breast carcinogenesis

- Loss of cell cycle and growth control, hyperplasia, dysplasia
- Oestrogen receptor lost in a third of breast cancers and a third of ER+ve recurrences
- No apoptosis when hormones limiting
- Loss of cell adhesion molecules
  - E-cadherin lost early in lobular carcinoma
- HER2 encodes epidermal growth factor receptor (EGF-R), abnormal oncogene product c-erbB2

Morphology

- Ductal carcinoma in situ (DCIS)
- Lobular carcinoma in situ (LCIS)

- Invasive ductal carcinoma
- Invasive lobular carcinoma

90% of carcinomas are DUCTAL, lobular carcinoma ~1%, all other types have much better prognosis

Terminal Ducto-Lobular Unit

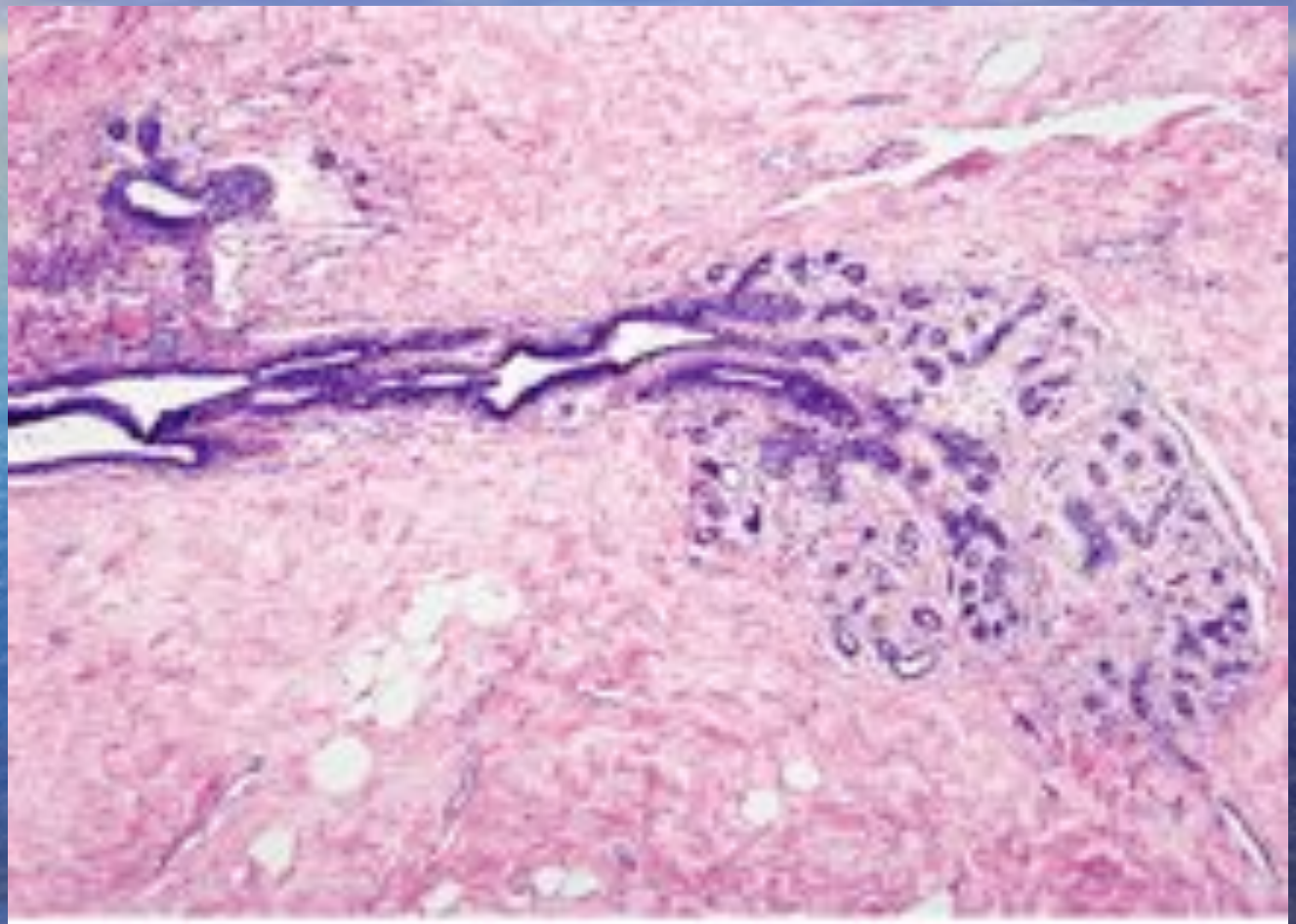

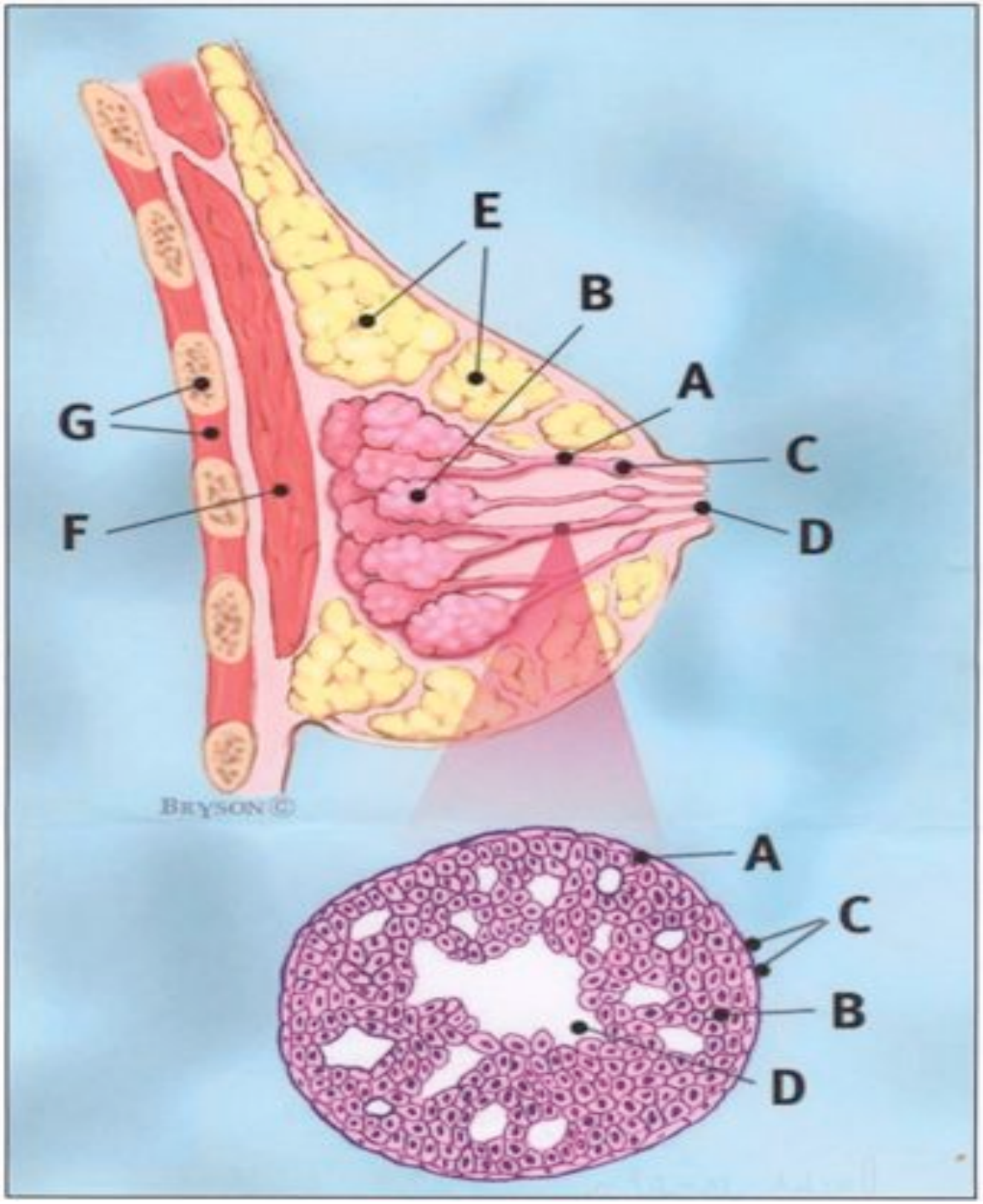
E
B
A
G
C
F
D
BRYSON ©
A
C
B
D

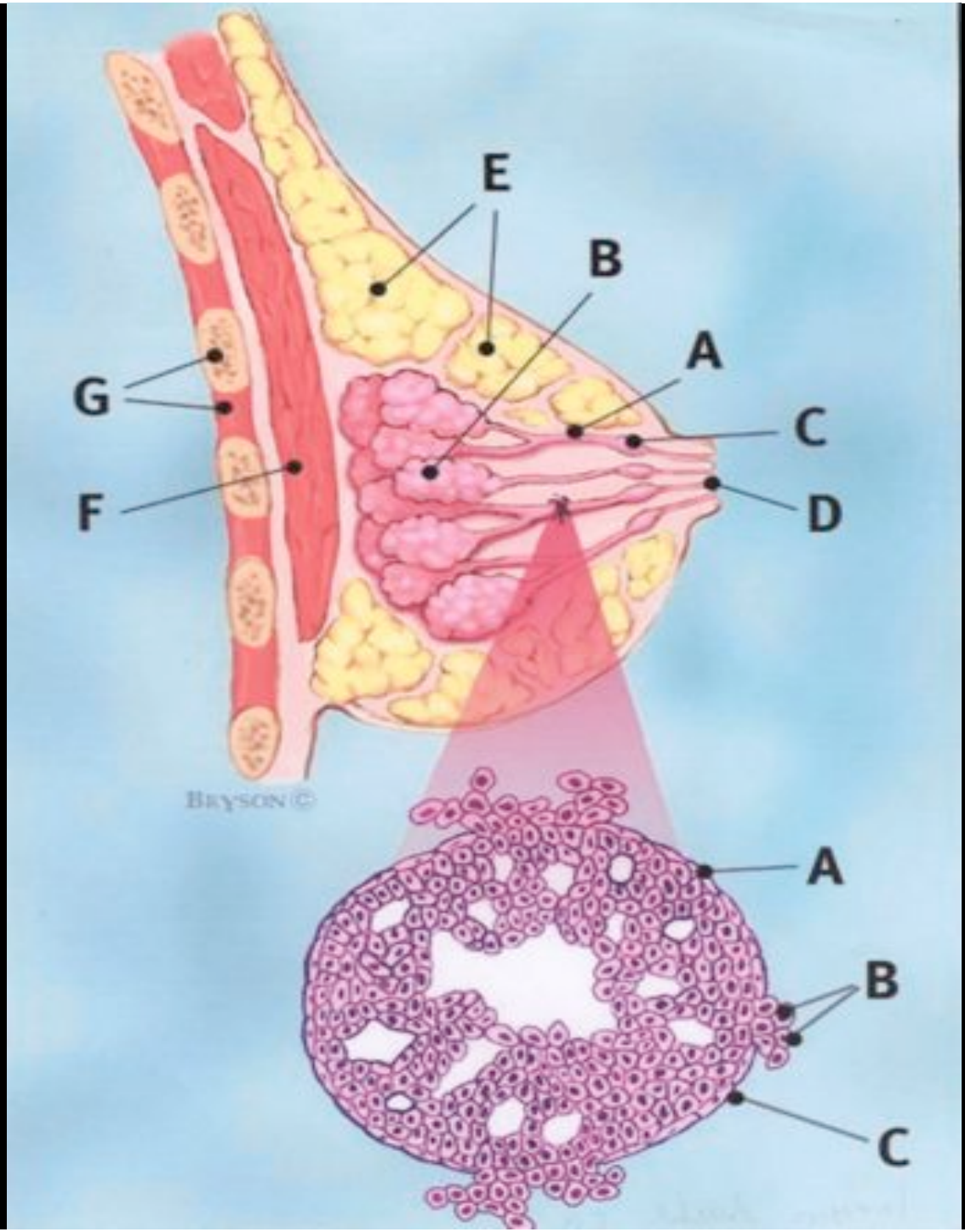
E
B
A
G
C
F
D
BRYSON ©
A
B
C

DCIS

- Solid-type DCIS
- Comedo-type (comedo-carcinoma)
- Cribriform-type
- Papillary

- May be associated microcalcification
- Usually associated with a mass. May be multifocal (rarely bilateral)

DCIS

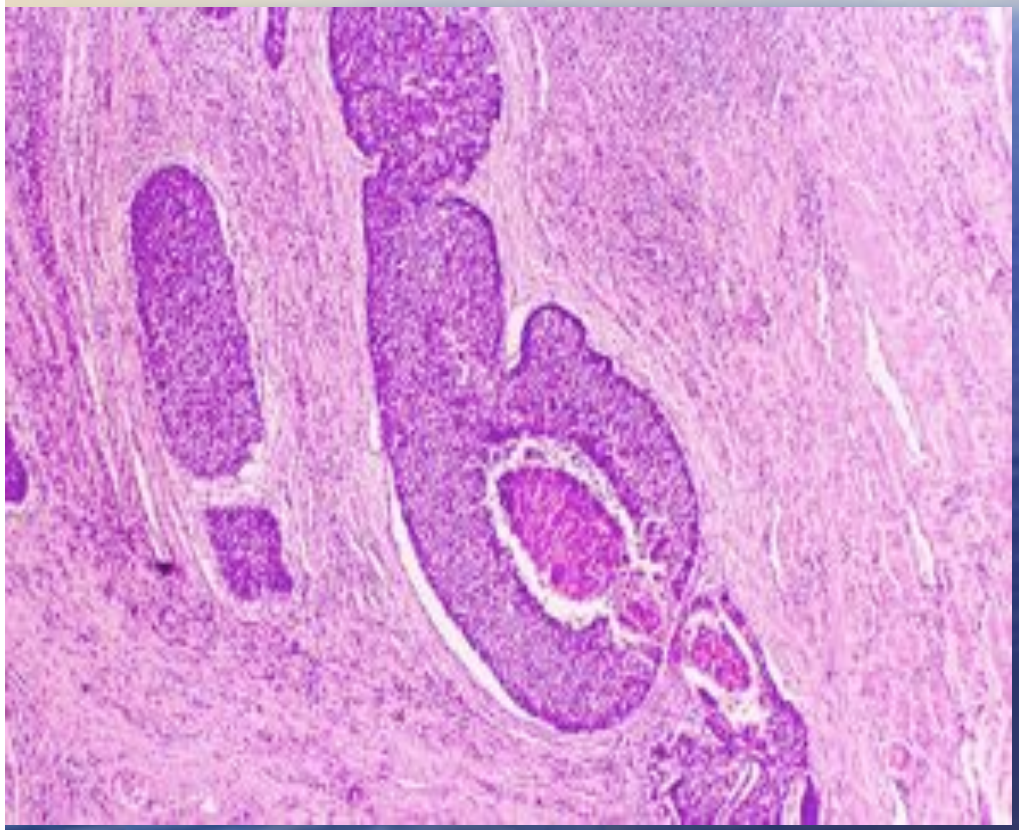

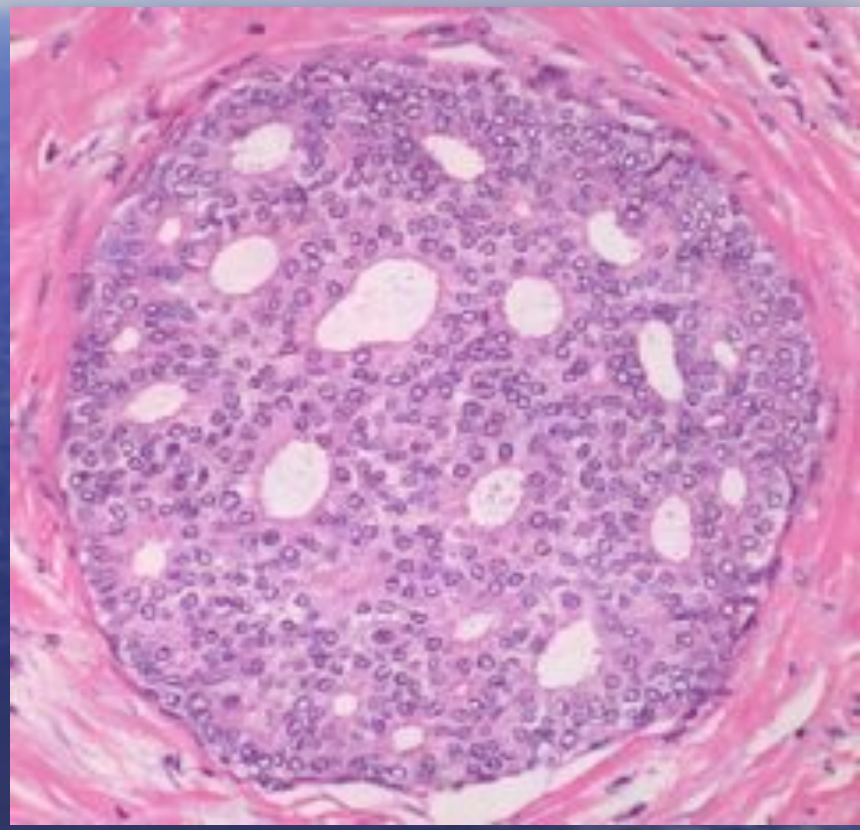

DCIS (2)

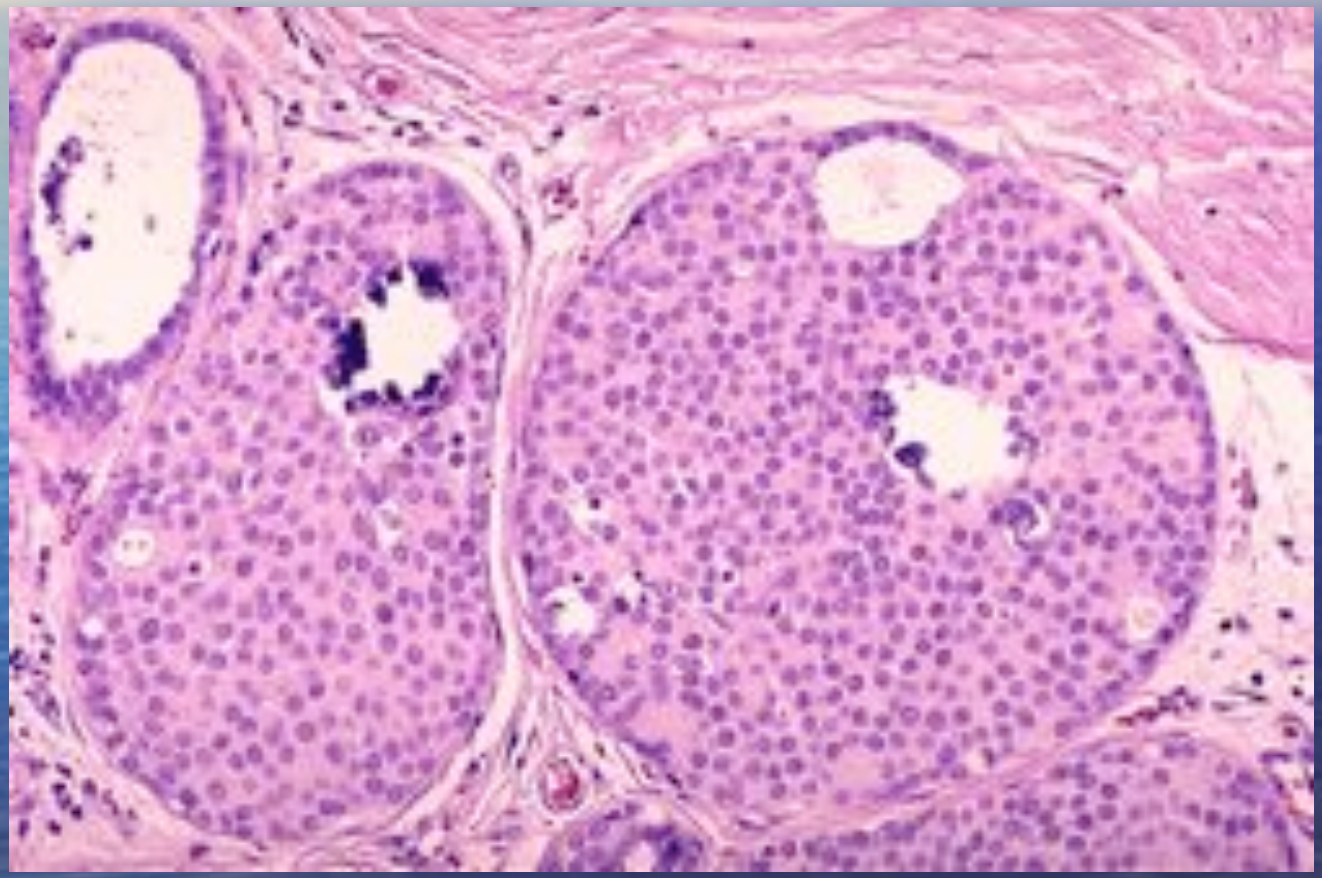

DCIS (3)

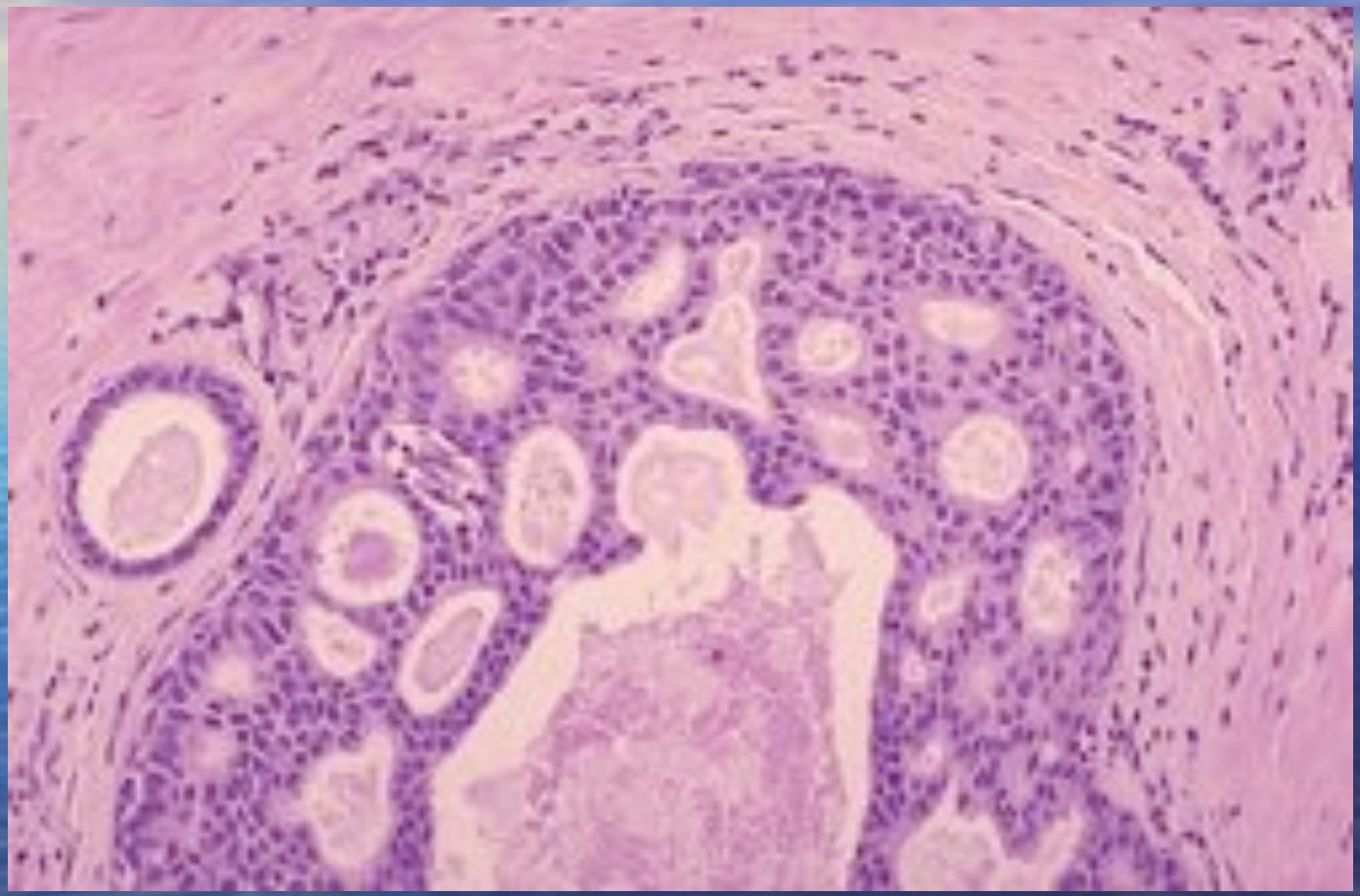

Paget's disease of the nipple (+ HMWCK immunohistochemistry)

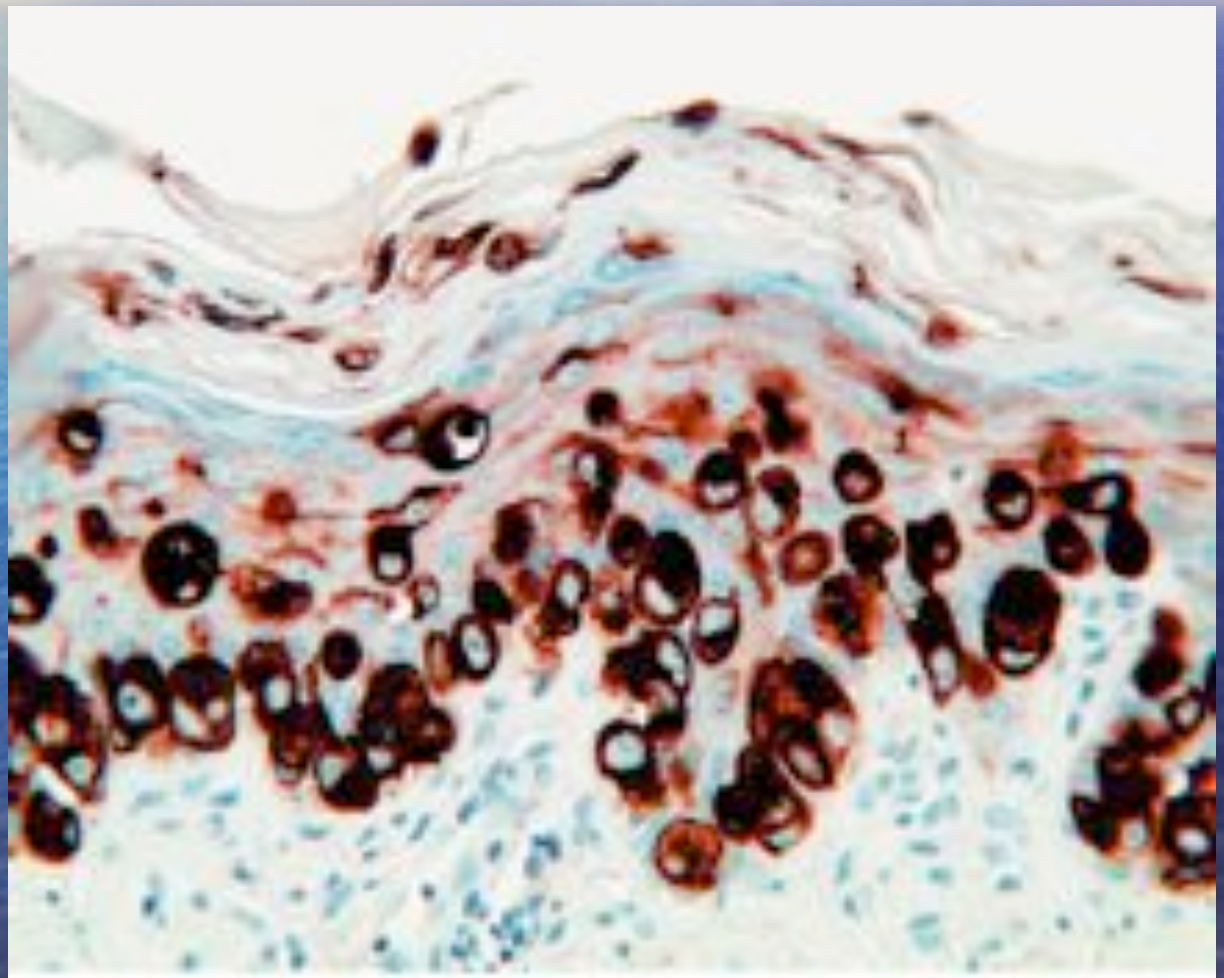

INVASIVE DUCTAL CARCINOMA

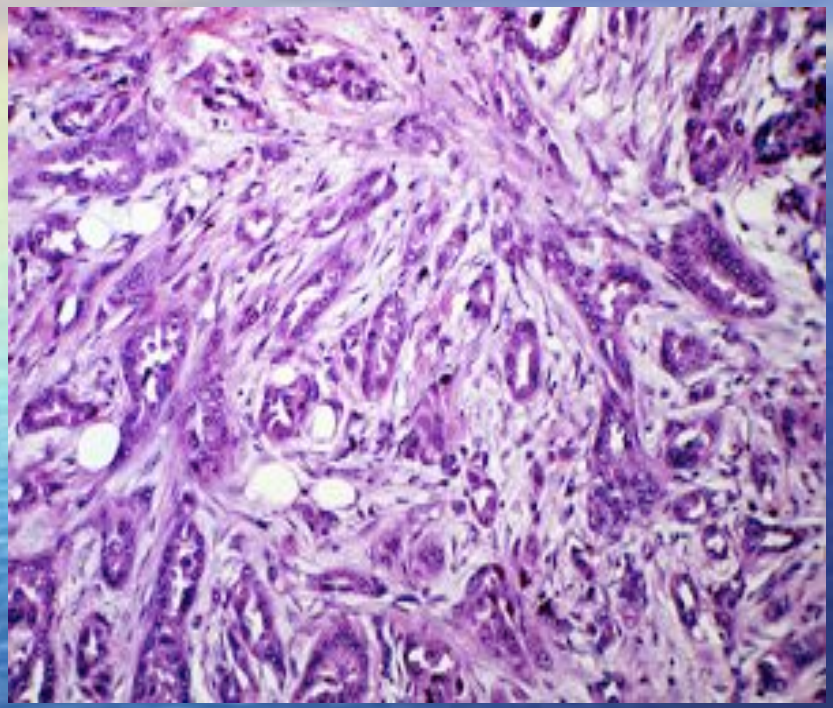

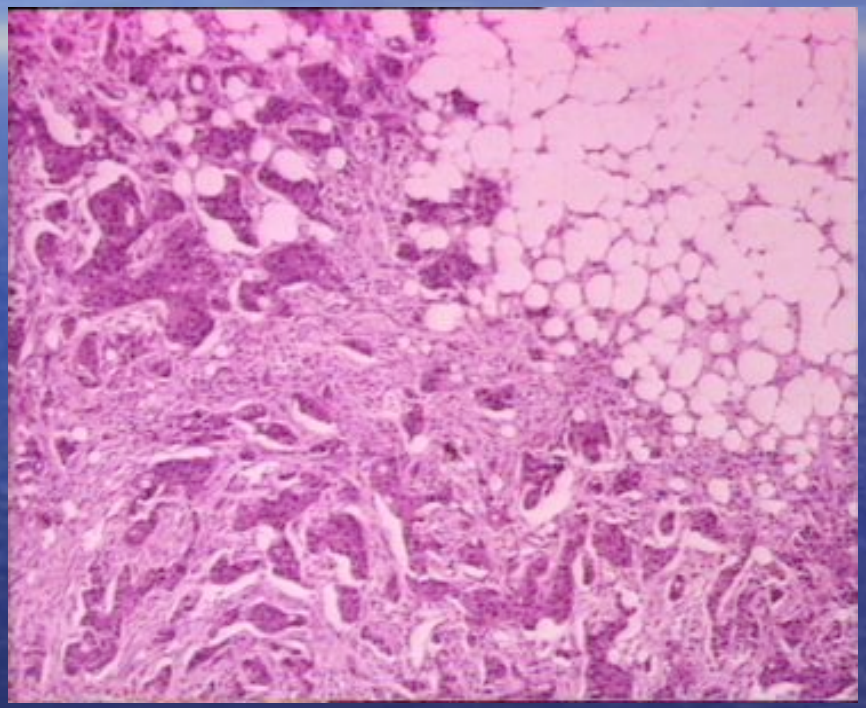

Tumour Grade (Histological)

- Modified Bloom-Richardson system:

- TUBULES (1-3) +
- PLEOMORPHISM (1-3) +
- MITOSES (1-3)

- Grade 1 = 3-5
- Grade 2 = 6-7
- Grade 3 = 8-9

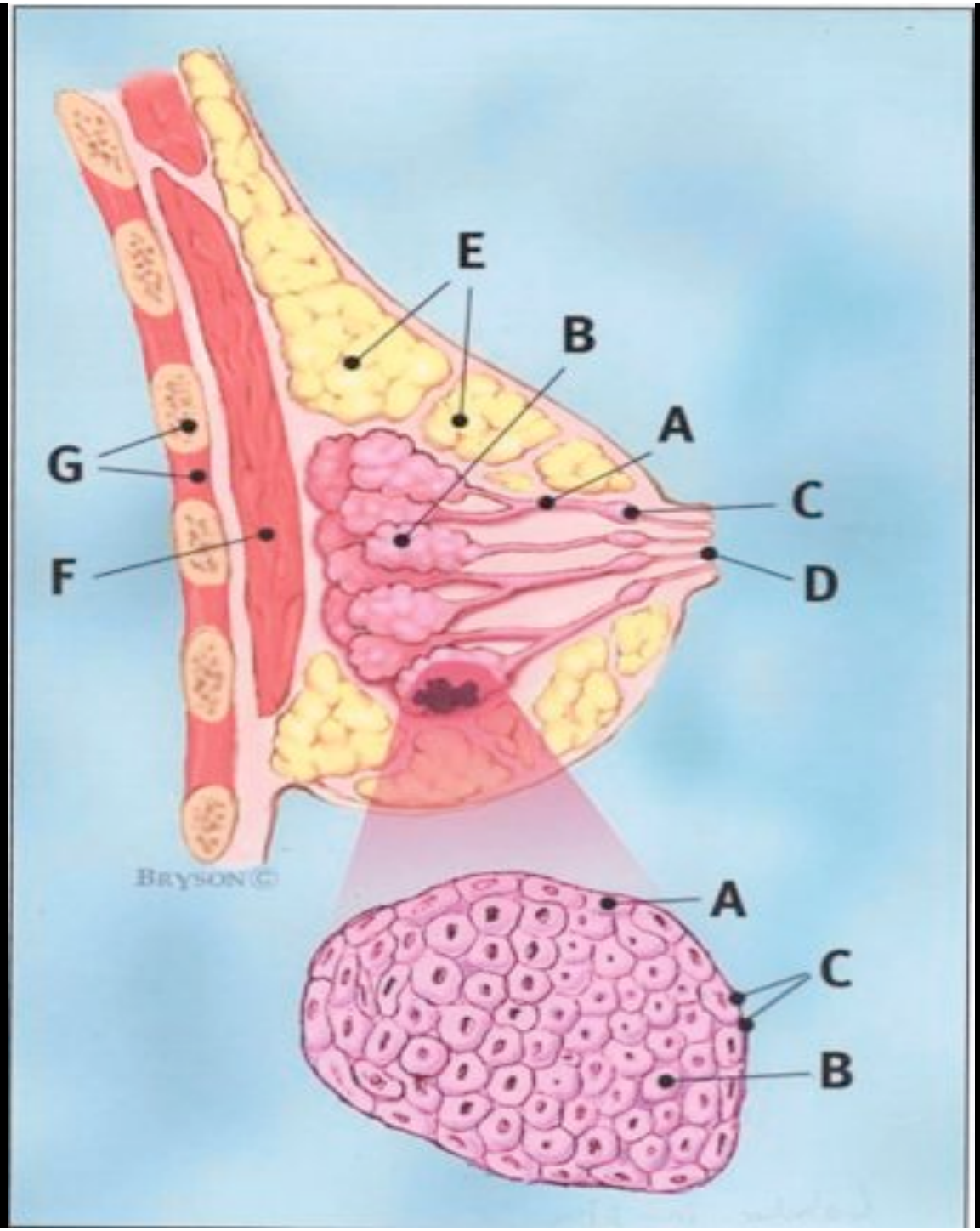
E
B
A
G
C
F
D
BRYSON ©
A
C
B

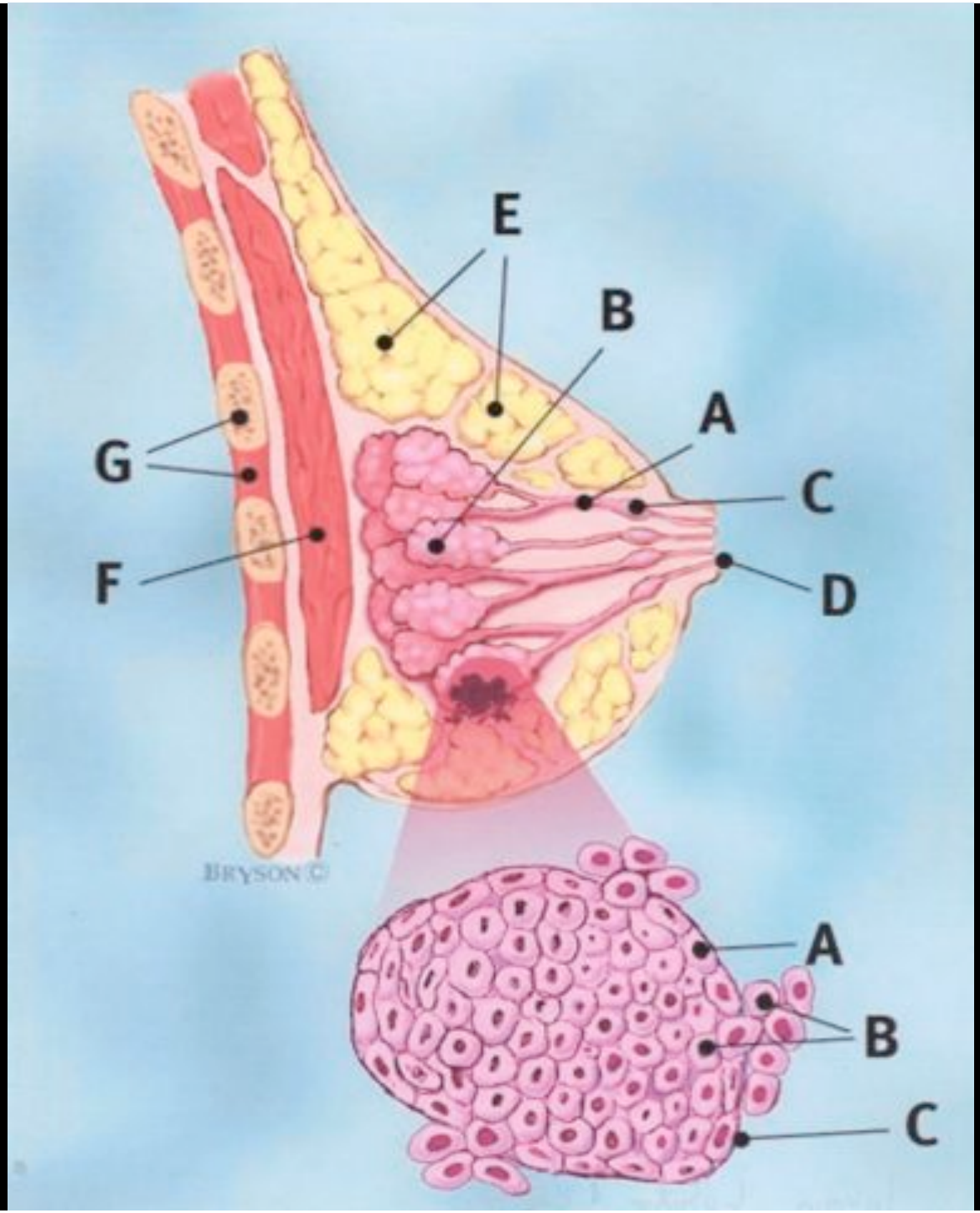
E
B
A
G
C
F
D
BRYSON ©
A
B
C

LCIS

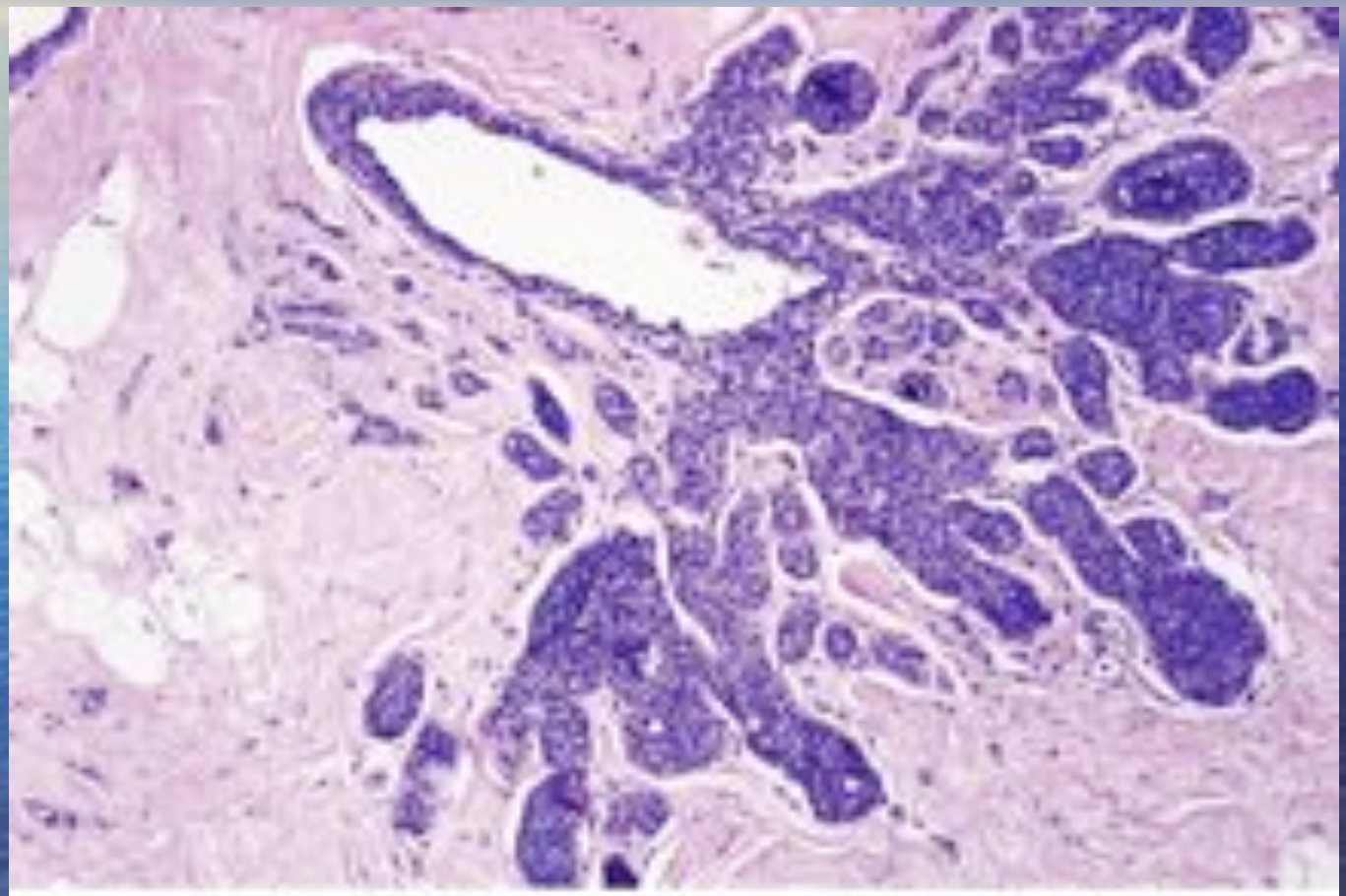

LCIS (2):

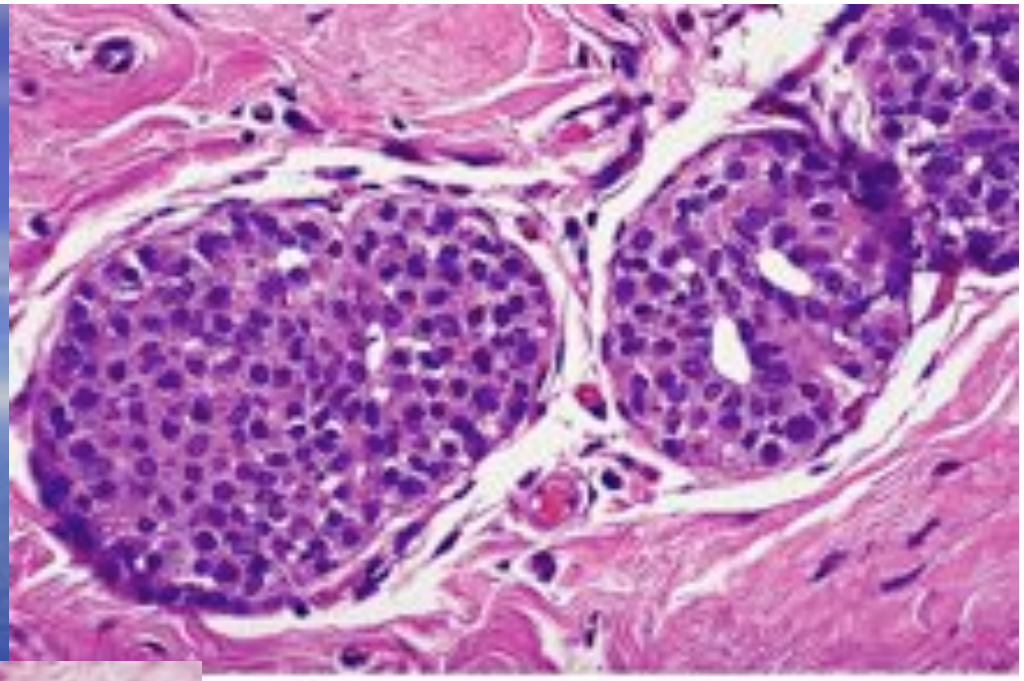

Inc 2004 Rosai and Ackerman's Surgical Pathology 9e

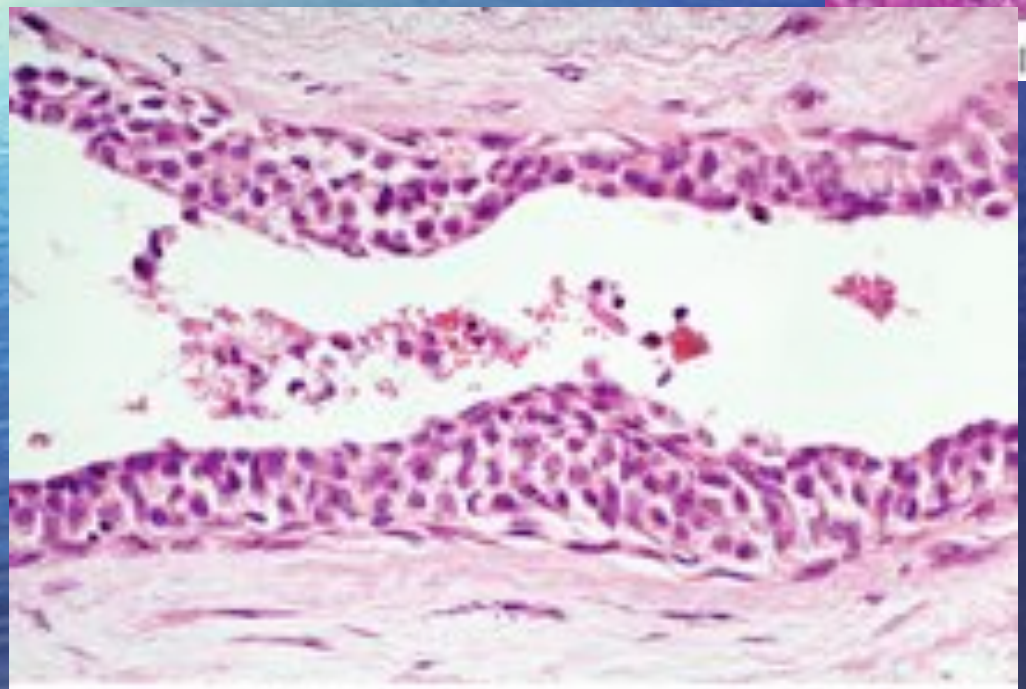

© Elsevier Inc 2004 Rosai and Ackerman's Surgical Pathology 9e

INVASIVE LOBULAR CARCINOMA

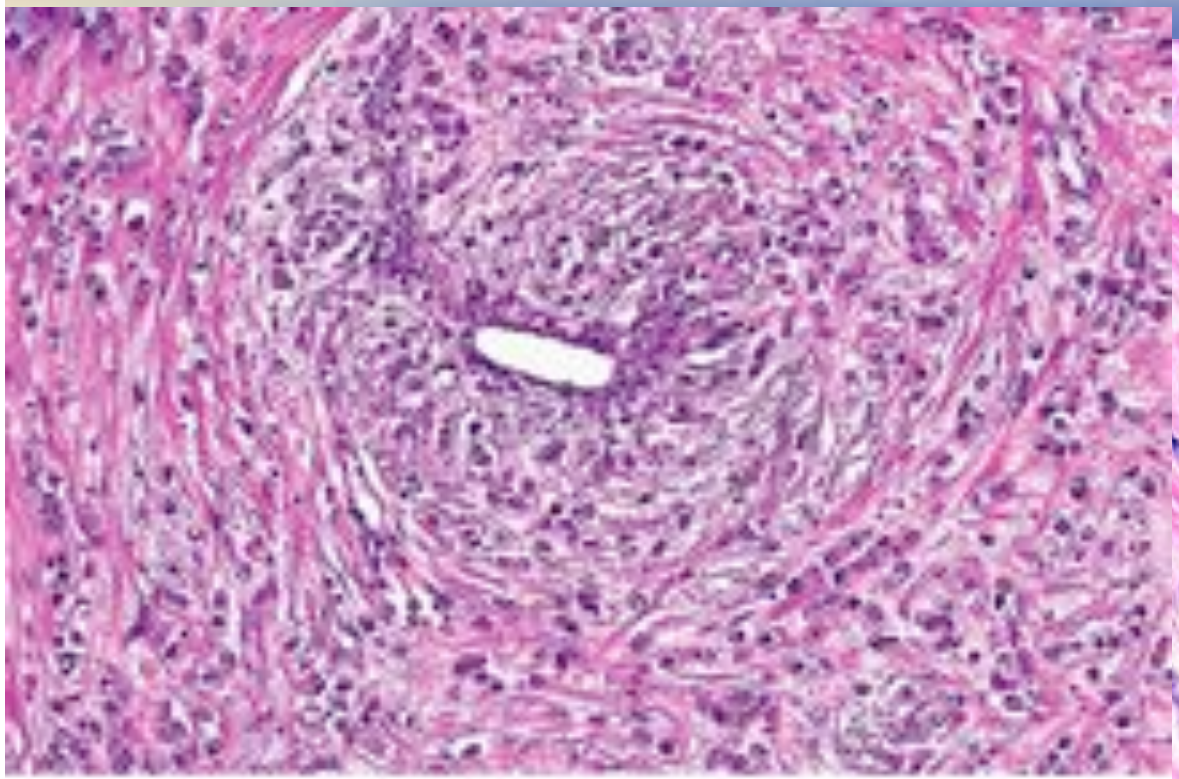

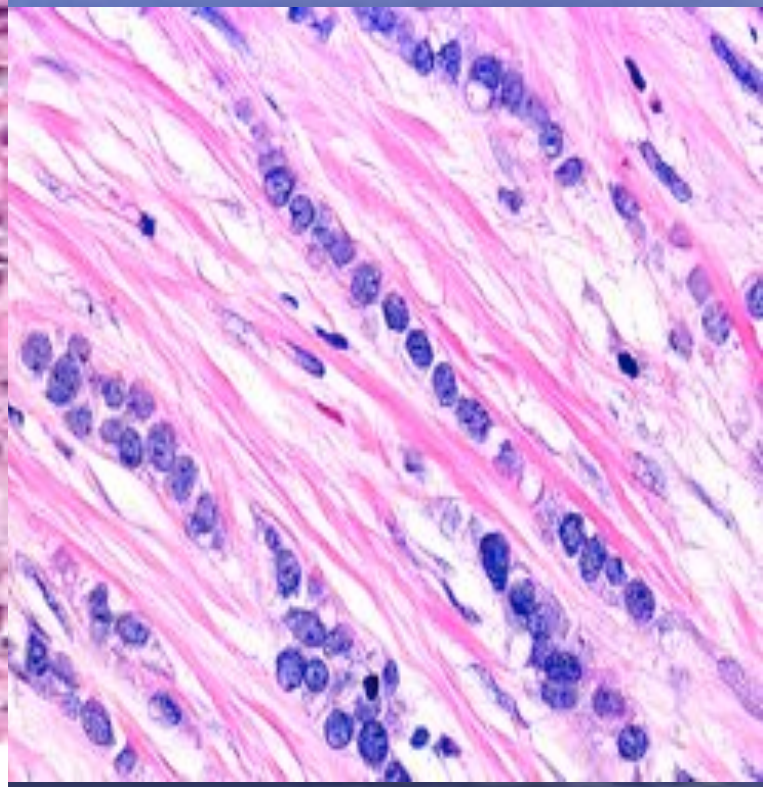

Tubular carcinoma

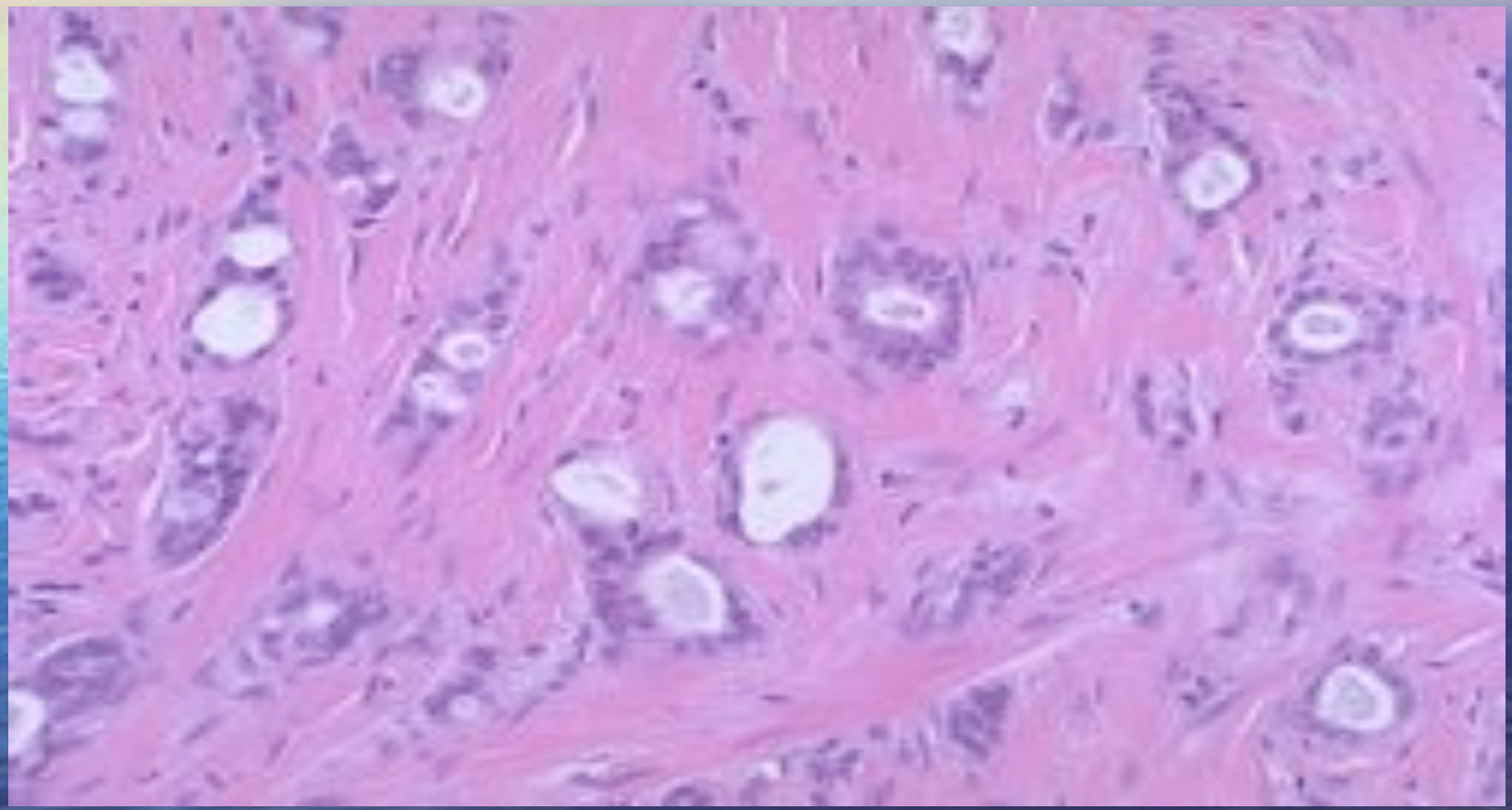

Tubular carcinoma has a better prognosis…

Colloid / mucinous carcinoma

As

Does

Mucinous

Carcinoma

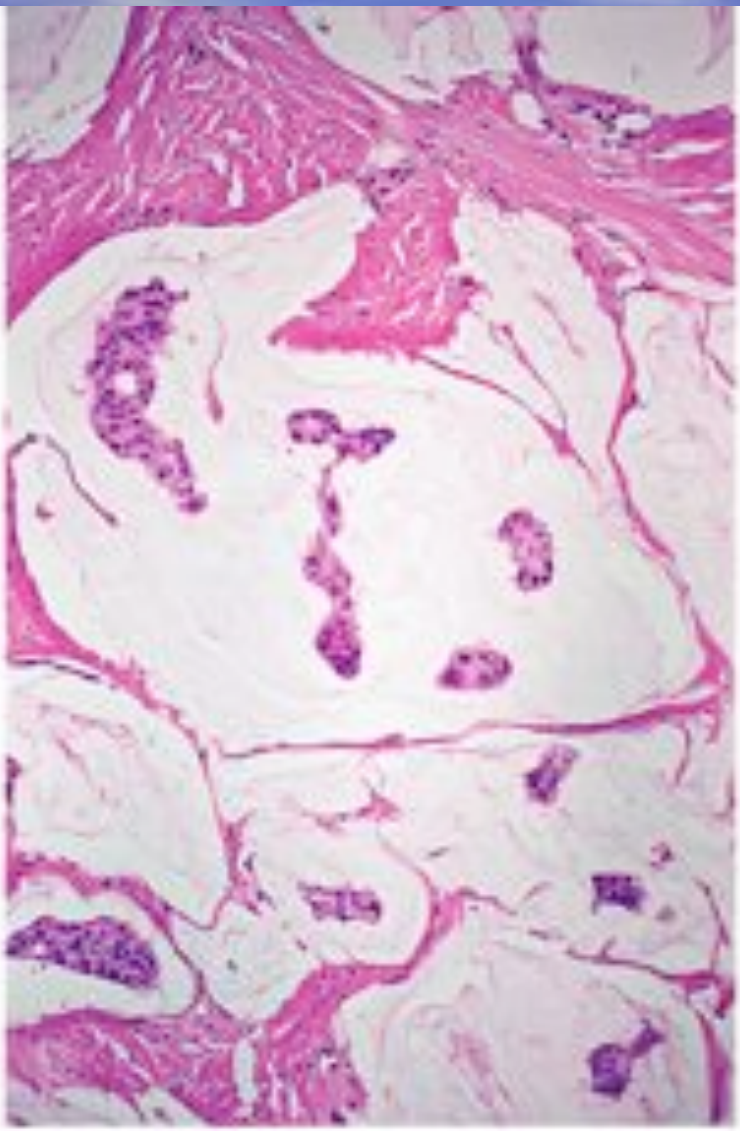

What are the management options for breast cancer?

Give three contra-indications to breast-conserving surgery

Treatment of breast carcinoma: surgery

- Breast conserving surgery (BCS)
- Wide local excision (WLE)
  +/- axillary sampling (at least four nodes)
  or axillary clearance

- Contra-indications to BCS
  - Pregnancy
  - Previous irradiation to breast
  - Multifocal/diffuse disease (including carcinoma in situ)
  - Positive margins/residual disease after BCS
  - Tumours >5cm*
  - Very large or very small breasts*

Lymphoedema after axillary surgery

Treatment of breast carcinoma:

- Modern treatment based on multimodal approach combining surgery, chemo, RT and HT
- Chemotherapy (CMF) / Radiotherapy
- Tamoxifen (if ER +ve)
- Arimidex (if ER +ve, postmenopasual and contraindication to Tamoxifen)
- Herceptin (if HER2 positive)

ER immunohistochemistry

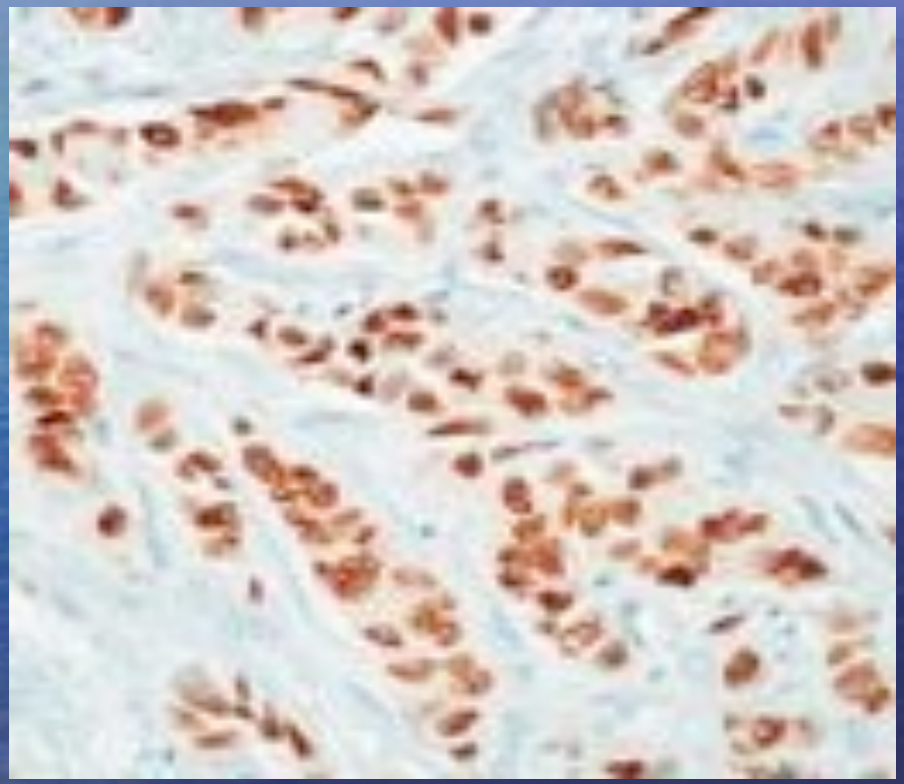

Herceptin

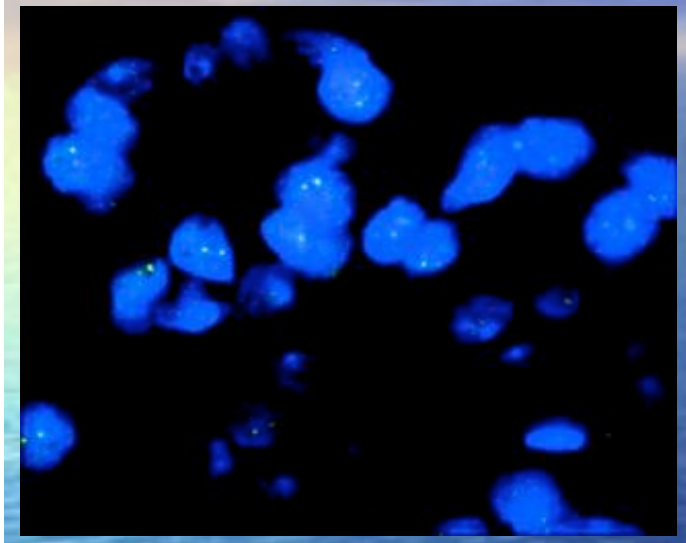

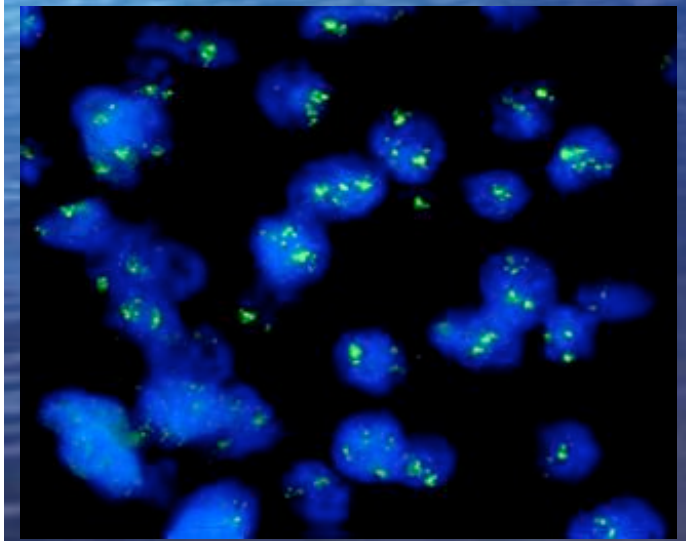

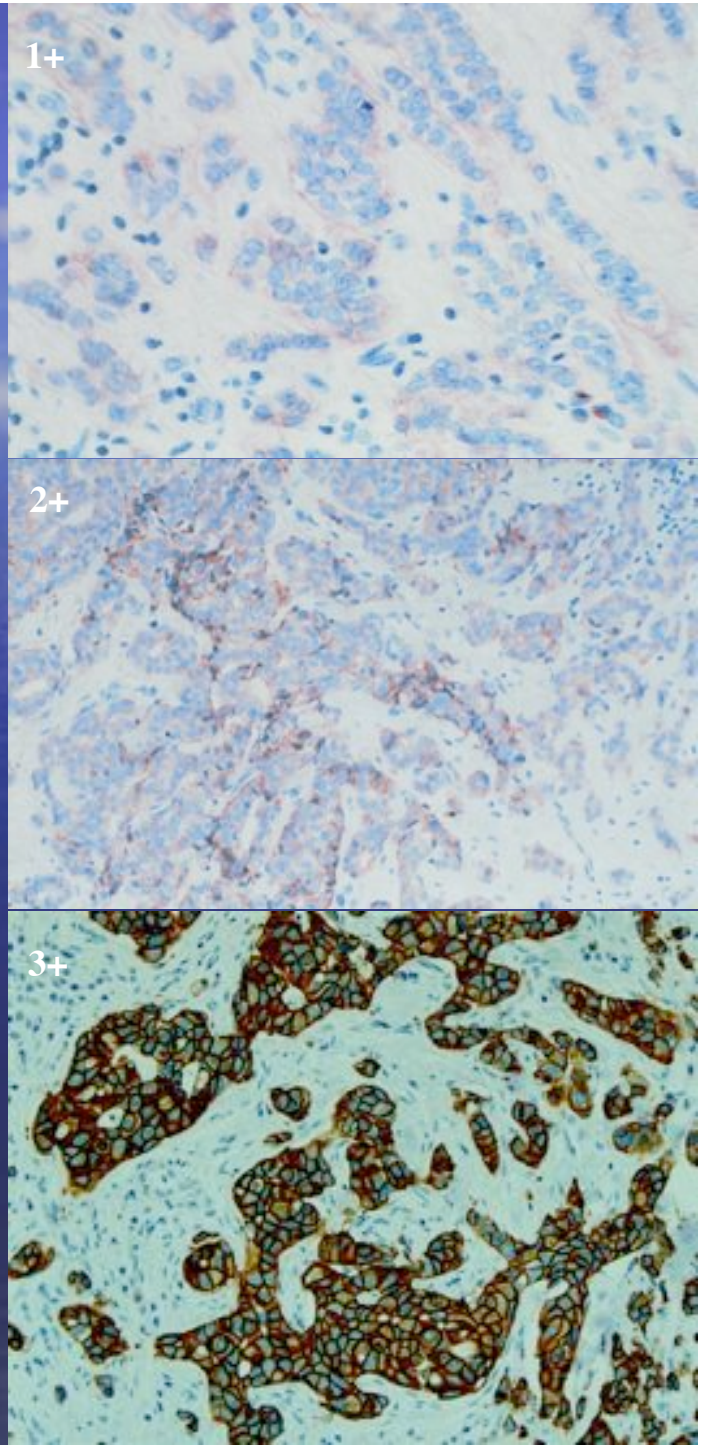

Spread of breast carcinoma

- **Direct**: skin, pec major, seratus anterior, chest wall
- **Lymphatic**: skin (Peau d'orange), axillary, internal thoracic. Later to supraclavicular, abdominal, mediastinal, groin, contralateral nodes.
- **Blood stream**: lungs, liver, bones (sites of red bone marrow) brain, ovaries, adrenal glands.
- **Trans-coelomic**: pleural (effusion) and peritoneal (ascites) in advanced disease.

Staging workup

- FBC, LFTs
- CXR
- CT scan
- Bone scan
- Liver USS

Staging breast carcinoma (TNM)

- **Stage 1** - Tumour less than 2cm in diameter with no LN involvement
- **Stage 2** - Tumour 2-5cm with or without LN involvement
- **Stage 3** - Tumour cells spread to axillary LN's but not to other parts of the body
- **Stage 4** - The cancer cells spread to other parts of the body

What have we talked about?

- Anatomy of breast
- Types of lumps in breast
- Features of benign and malignant lumps
- Clinical assessment, symptoms and signs
- Genetic and hormonal factors including HER2
- Difference between DCIS and LCIS
- Mastectomy vs breast conservation
- Chemo, hormonal therapy and Herceptin

Questions?