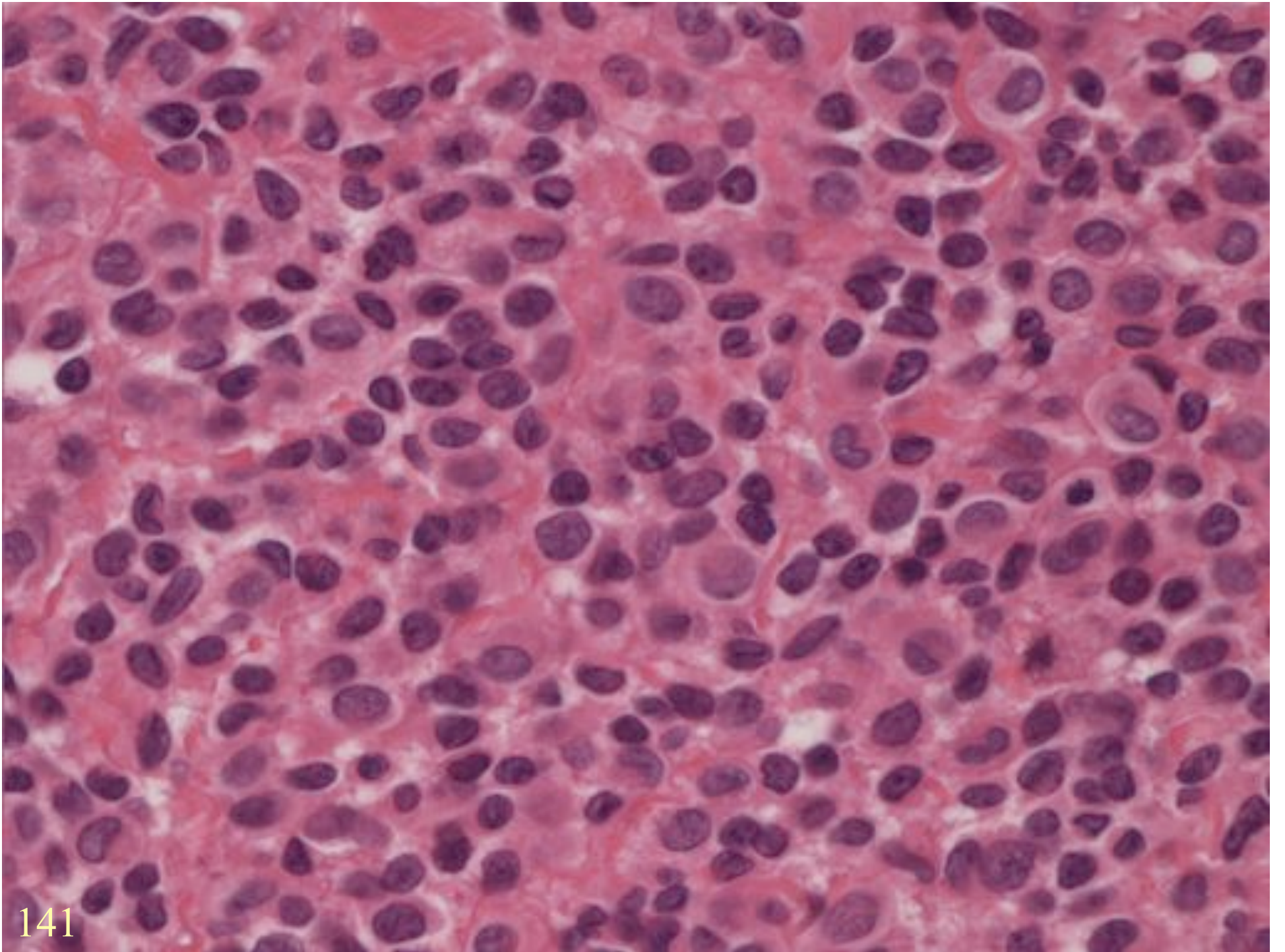


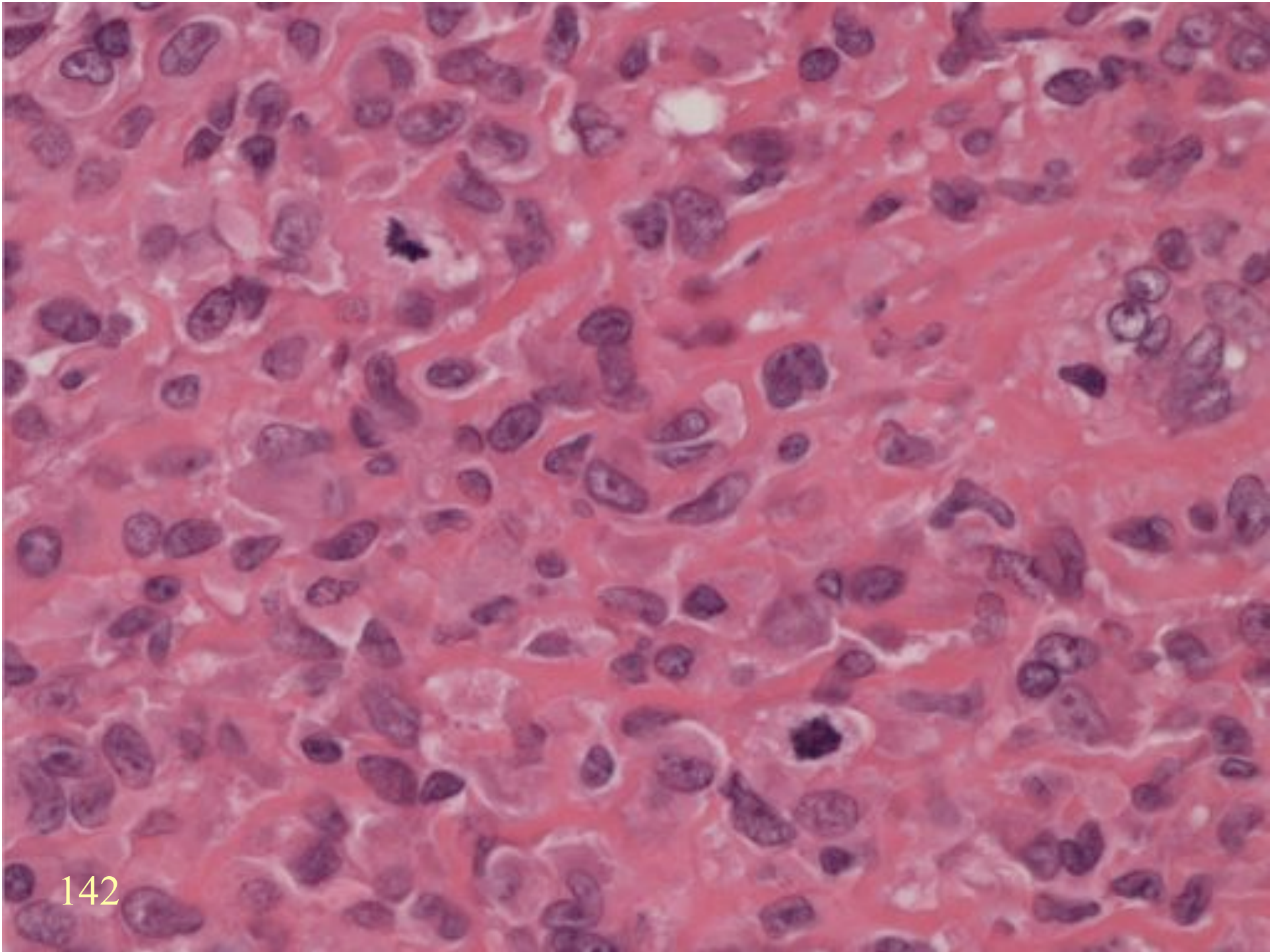
LEIOMYOMA of DEEP SOFT TISSUE

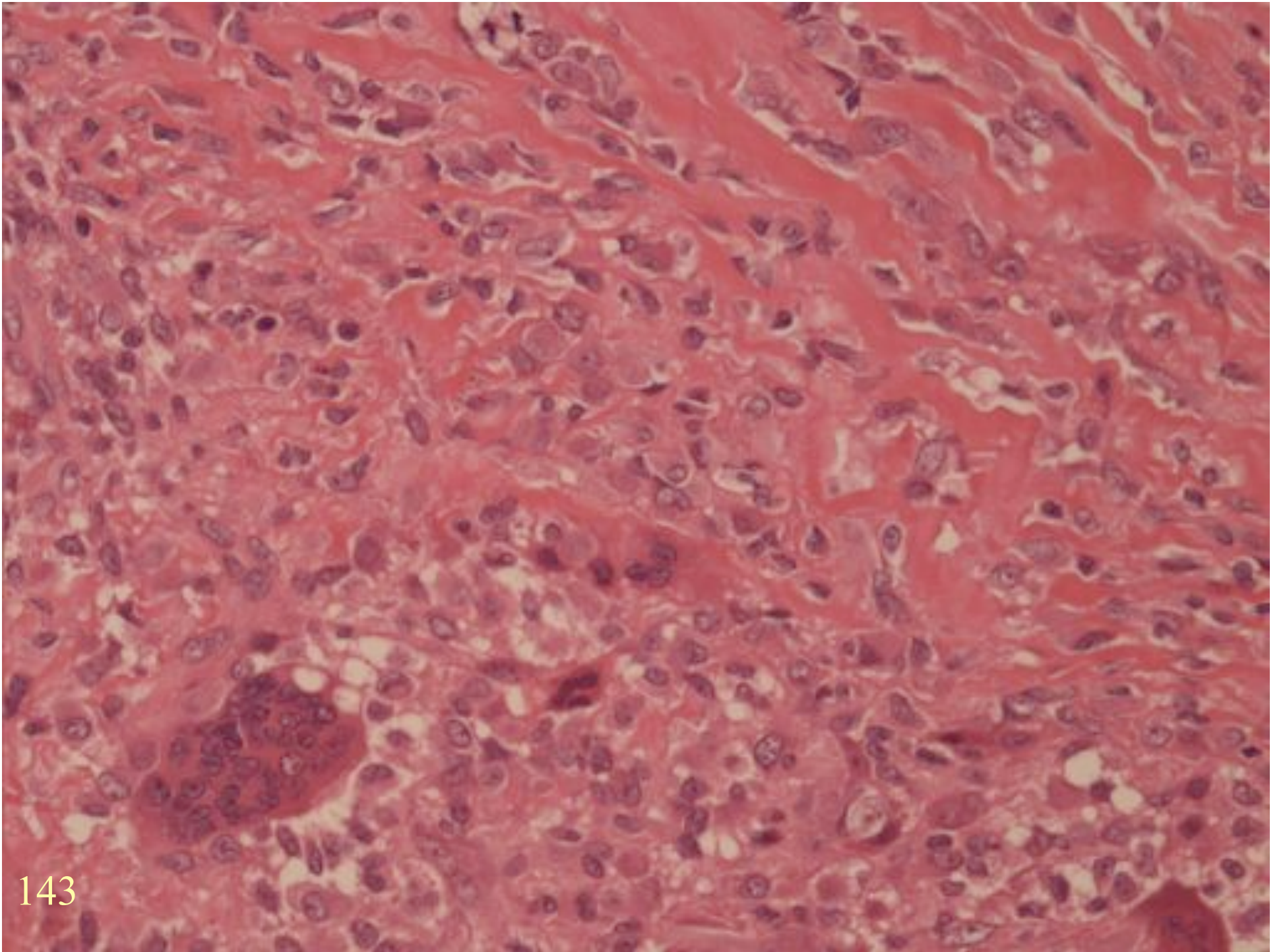
- Somatic type
- Gynaecologic type

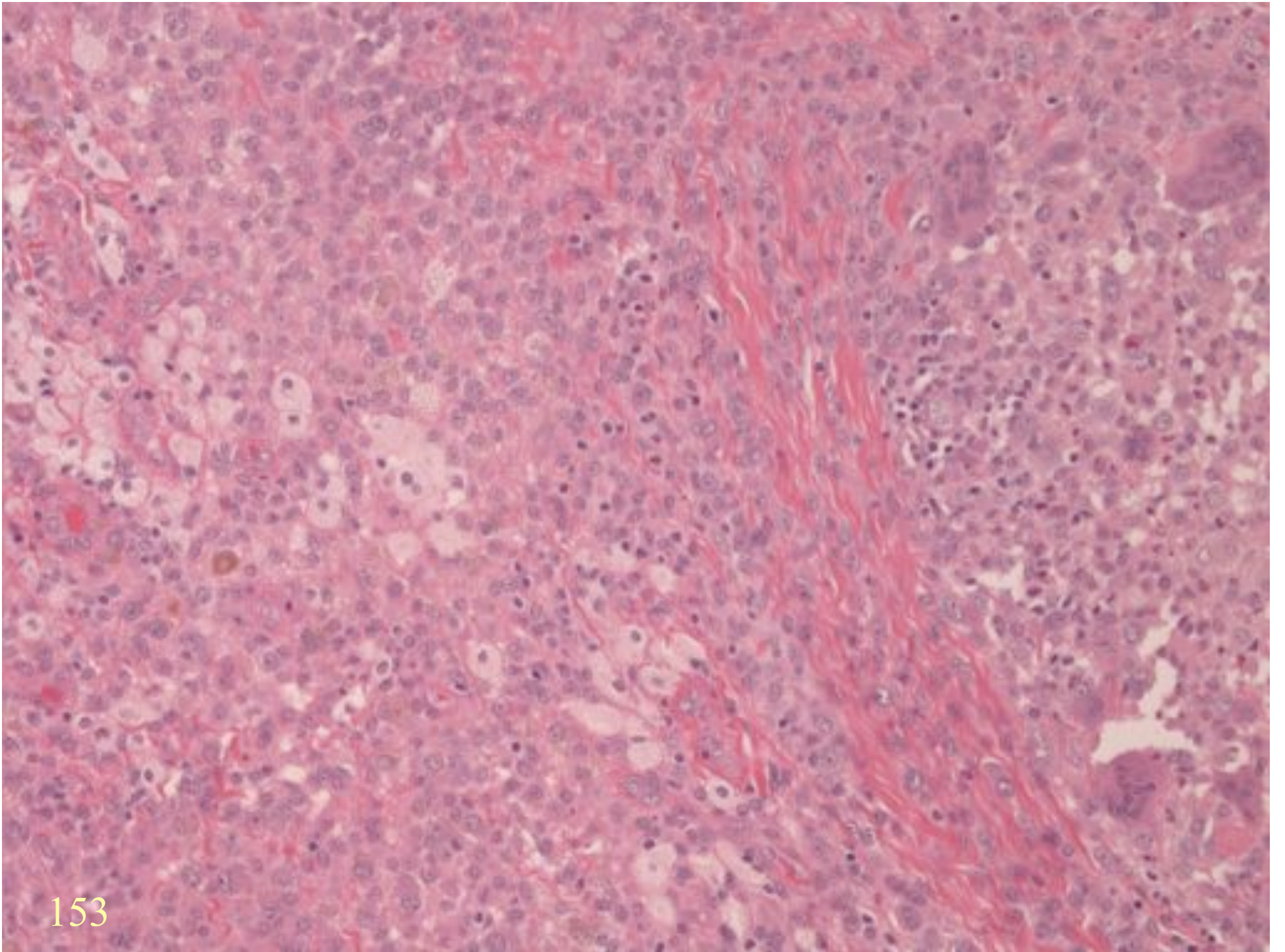
ROUND CELL LESIONS

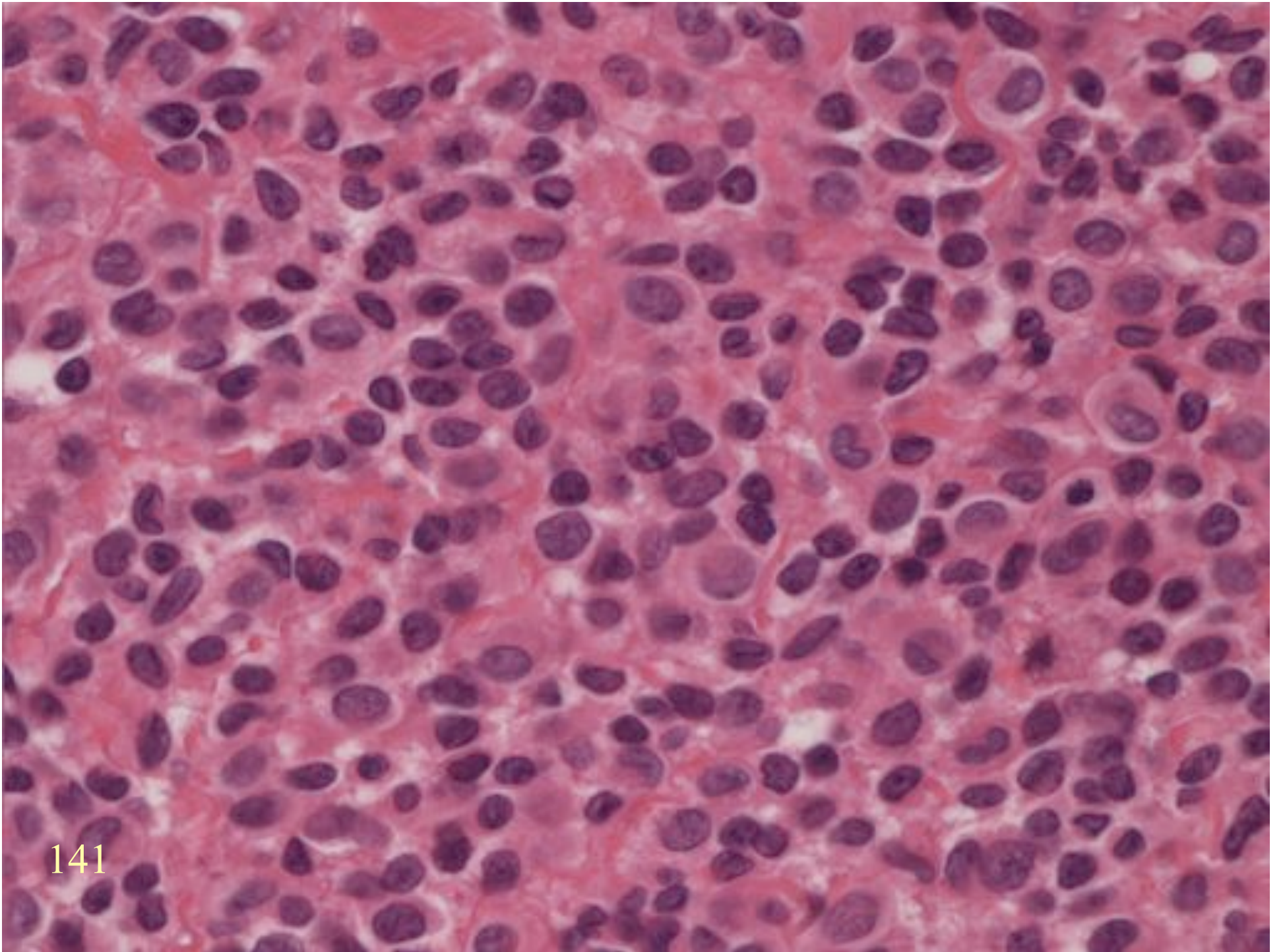
TENOSYNOVIAL GIANT
CELL TUMOUR





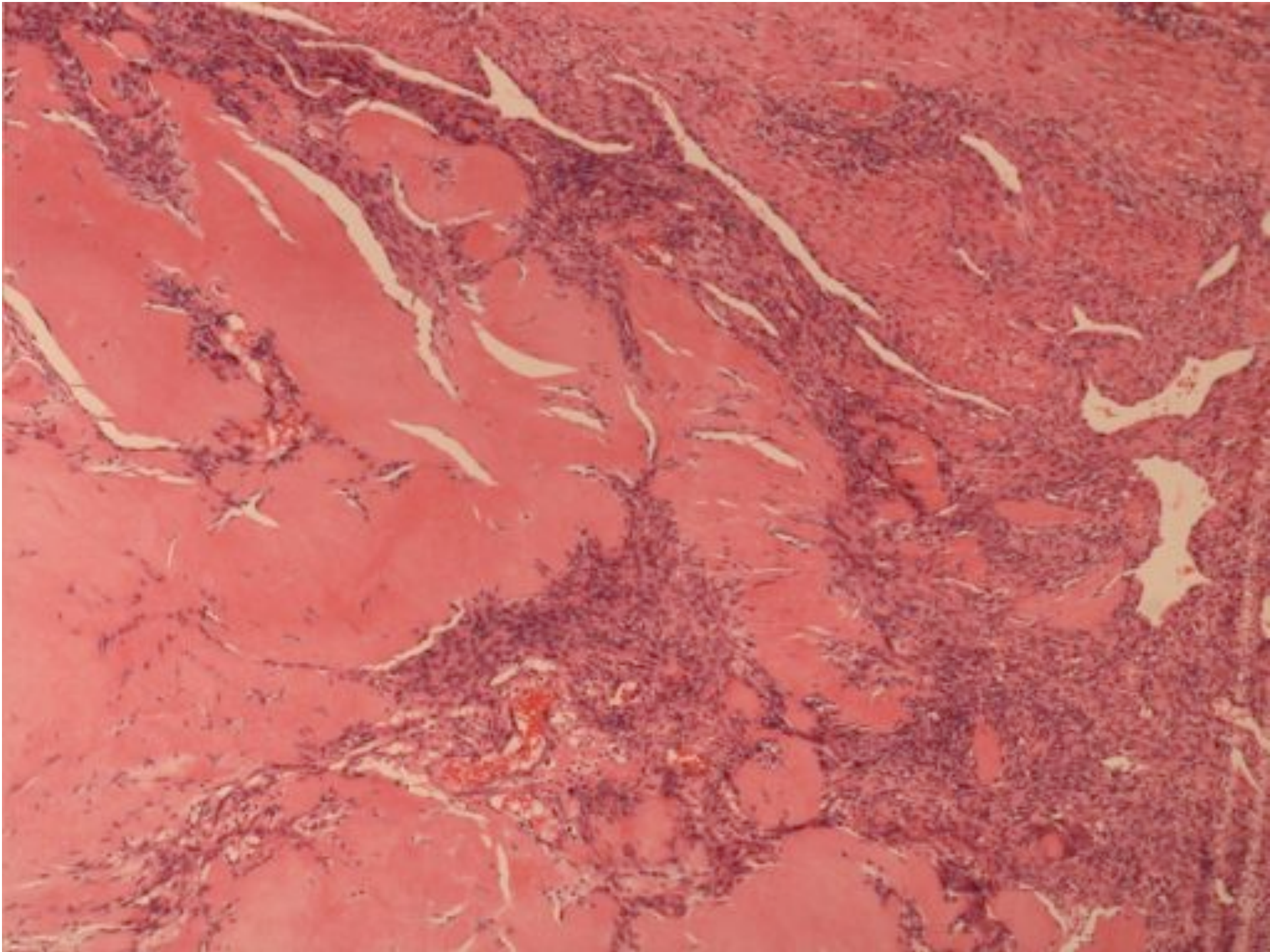


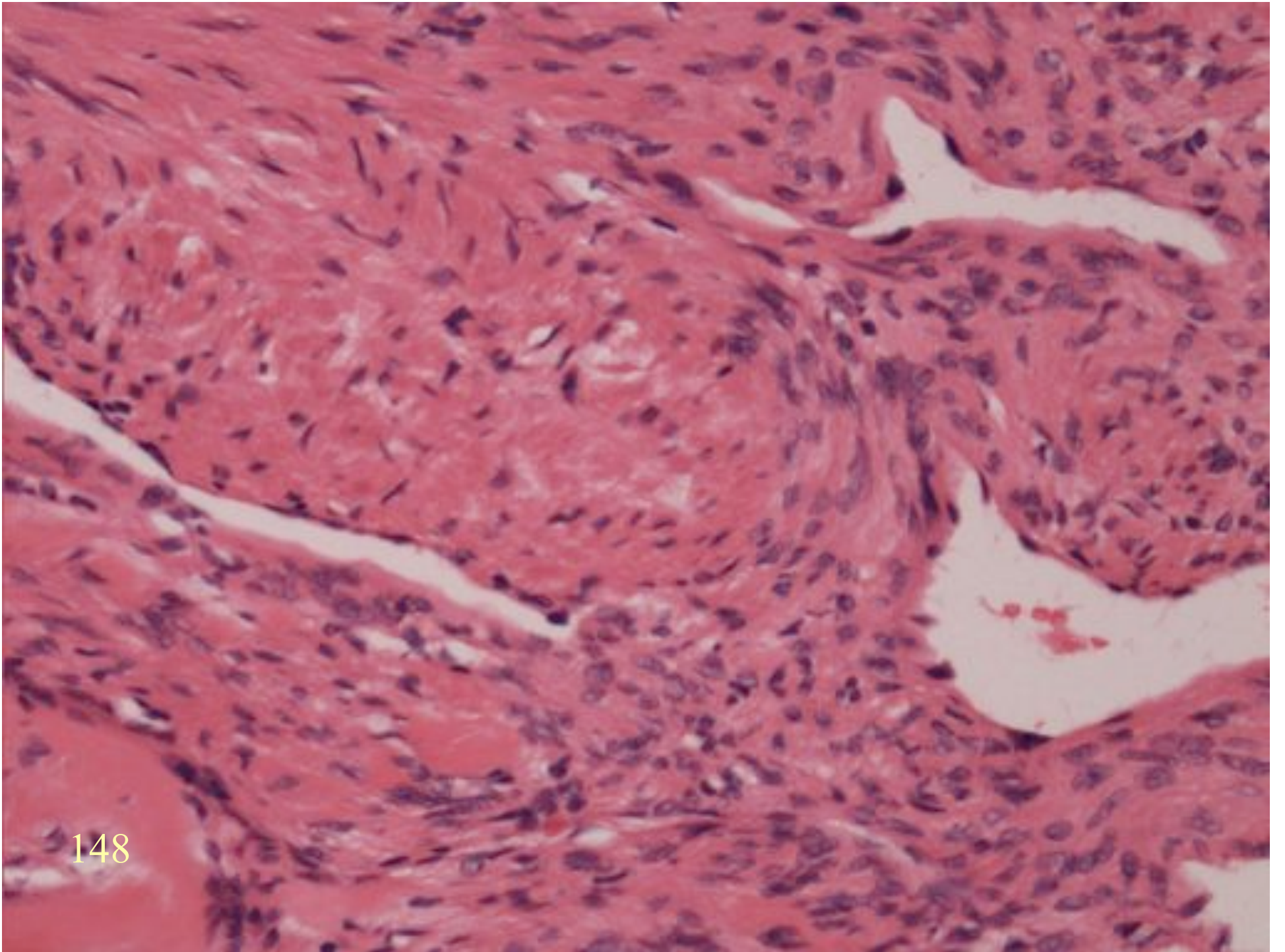




MYOFIBROMA

- Round cell pattern
- Necrosis
- Intravascular growth





148

ROUND CELL MALIGNANCY

ROUND CELL MALIGNANCY

- Small cell carcinoma
- Lymphoma
- Melanoma
- Round cell sarcoma
- Mesothelioma

ROUND CELL SARCOMA

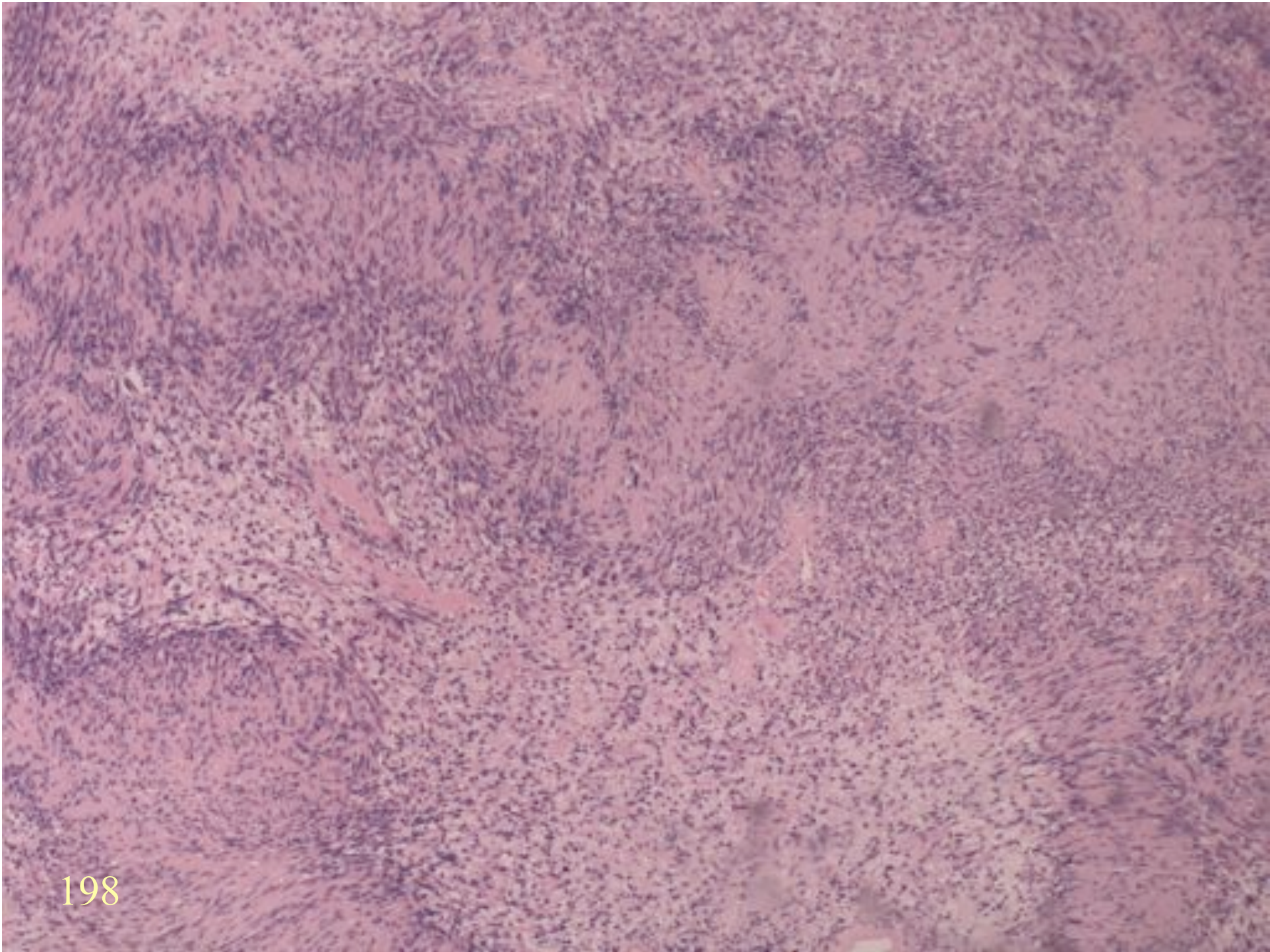
ROUND CELL SARCOMA

- Ewing's/PNET
- Rhabdomyosarcoma.
- Neuroblastoma
- Round cell liposarcoma
- P/D synovial sarcoma
- Mesenchymal chondrosarcoma
- Osteosarcoma

PERIPHERAL NERVE LESIONS

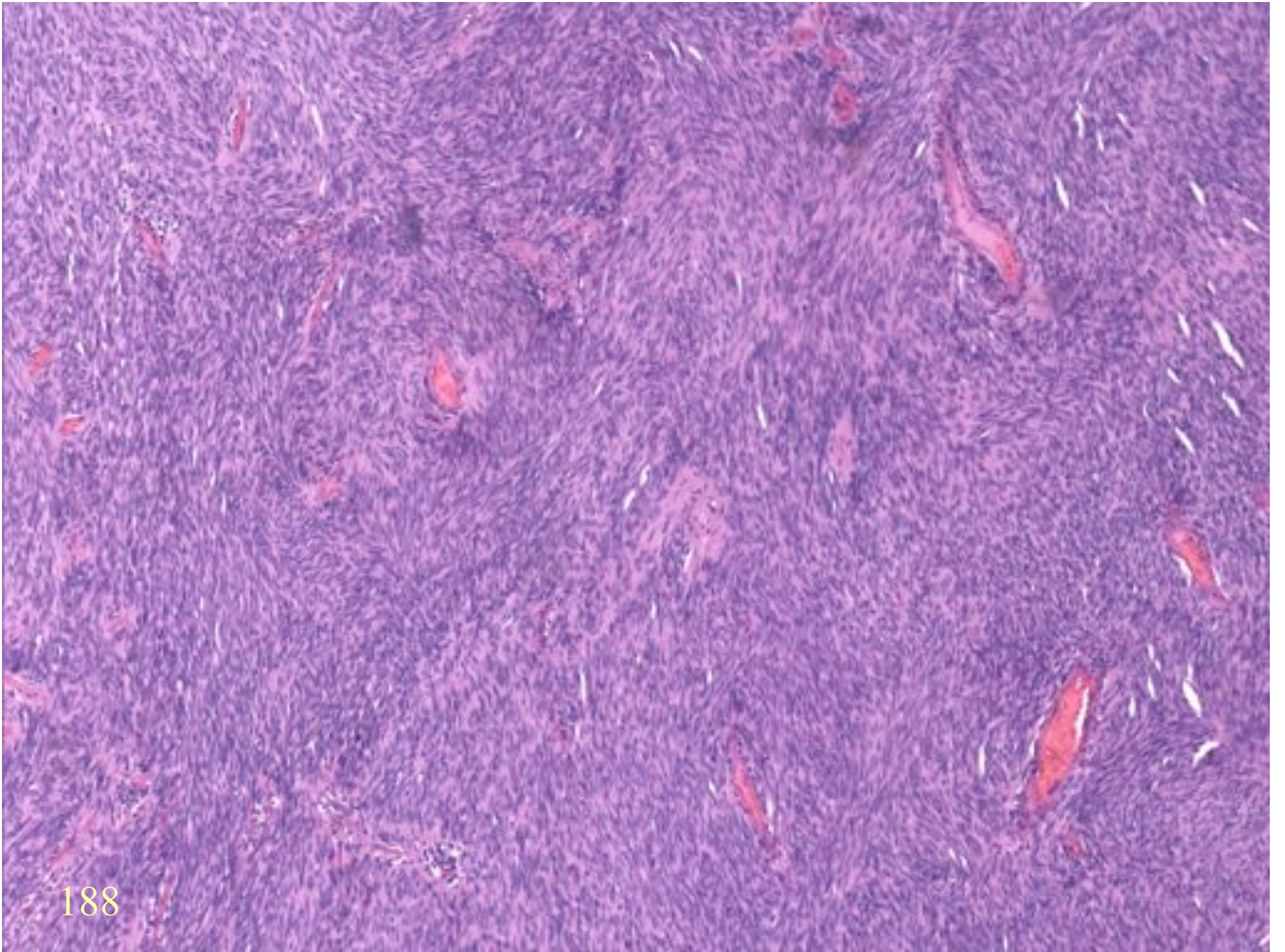
NEURILEMOMA / BENIGN SCHWANNOMA

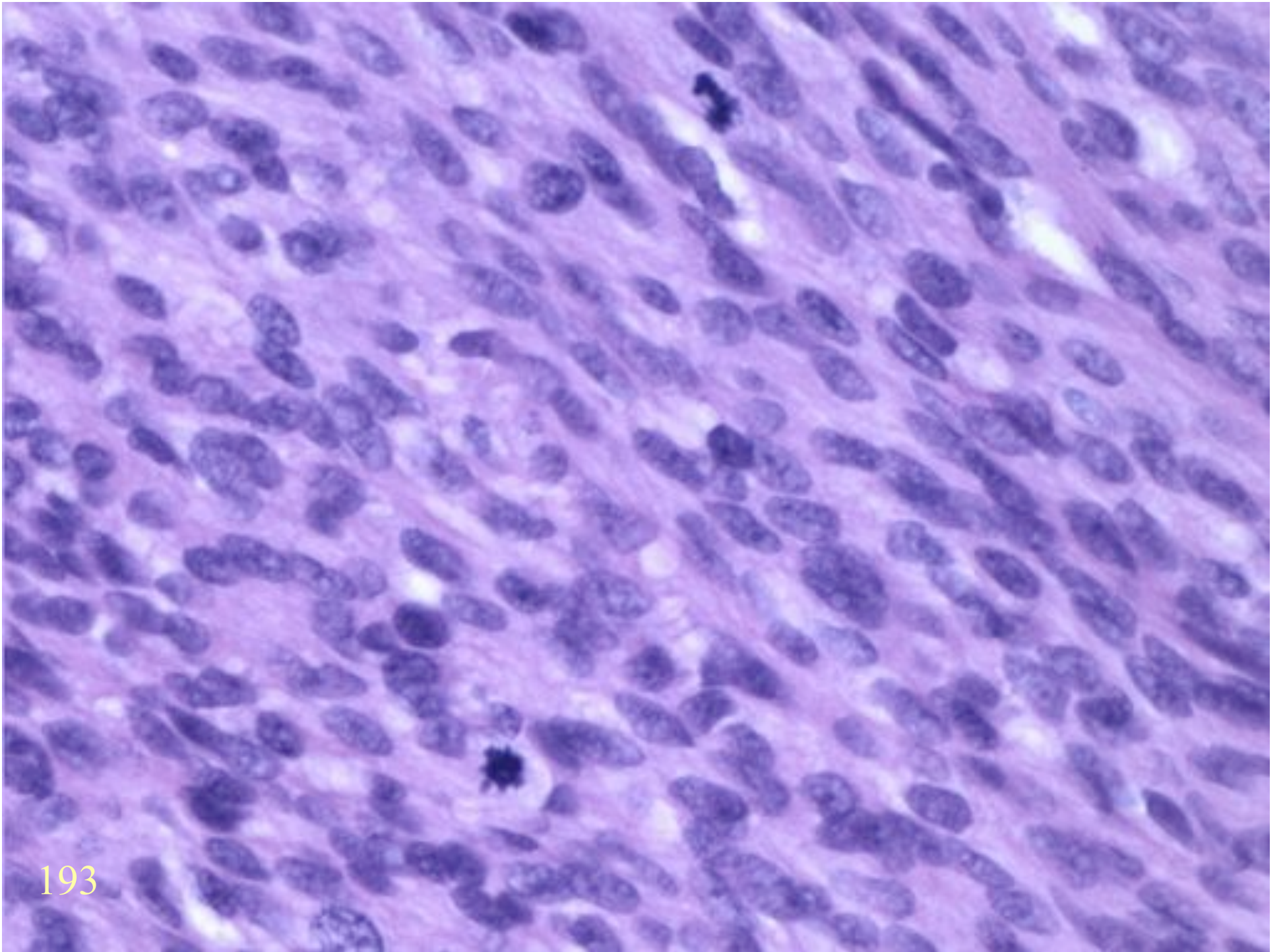
- Cellular variant (cellular Schwannoma)
- Pleomorphic variant (ancient Schwannoma)

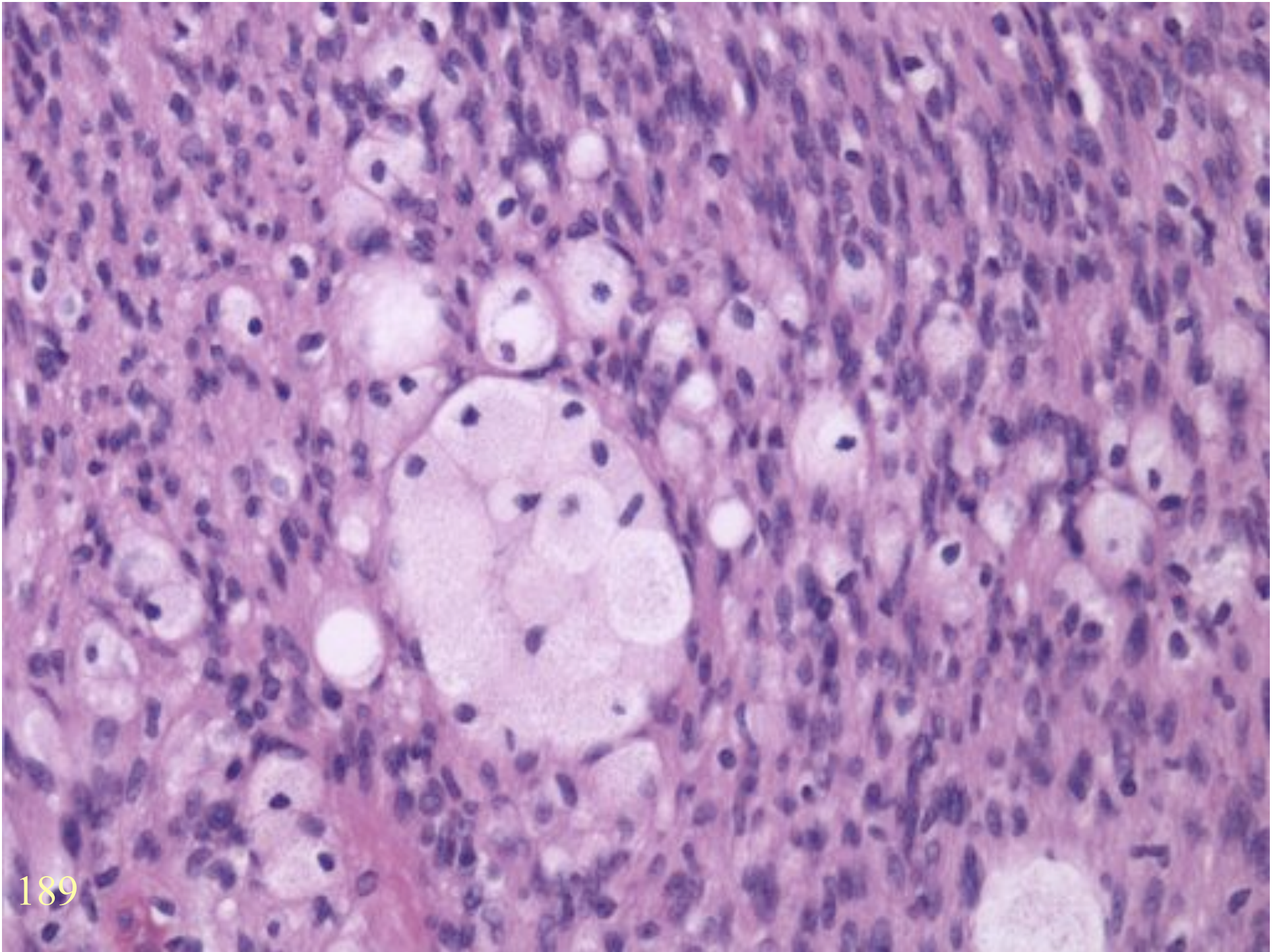


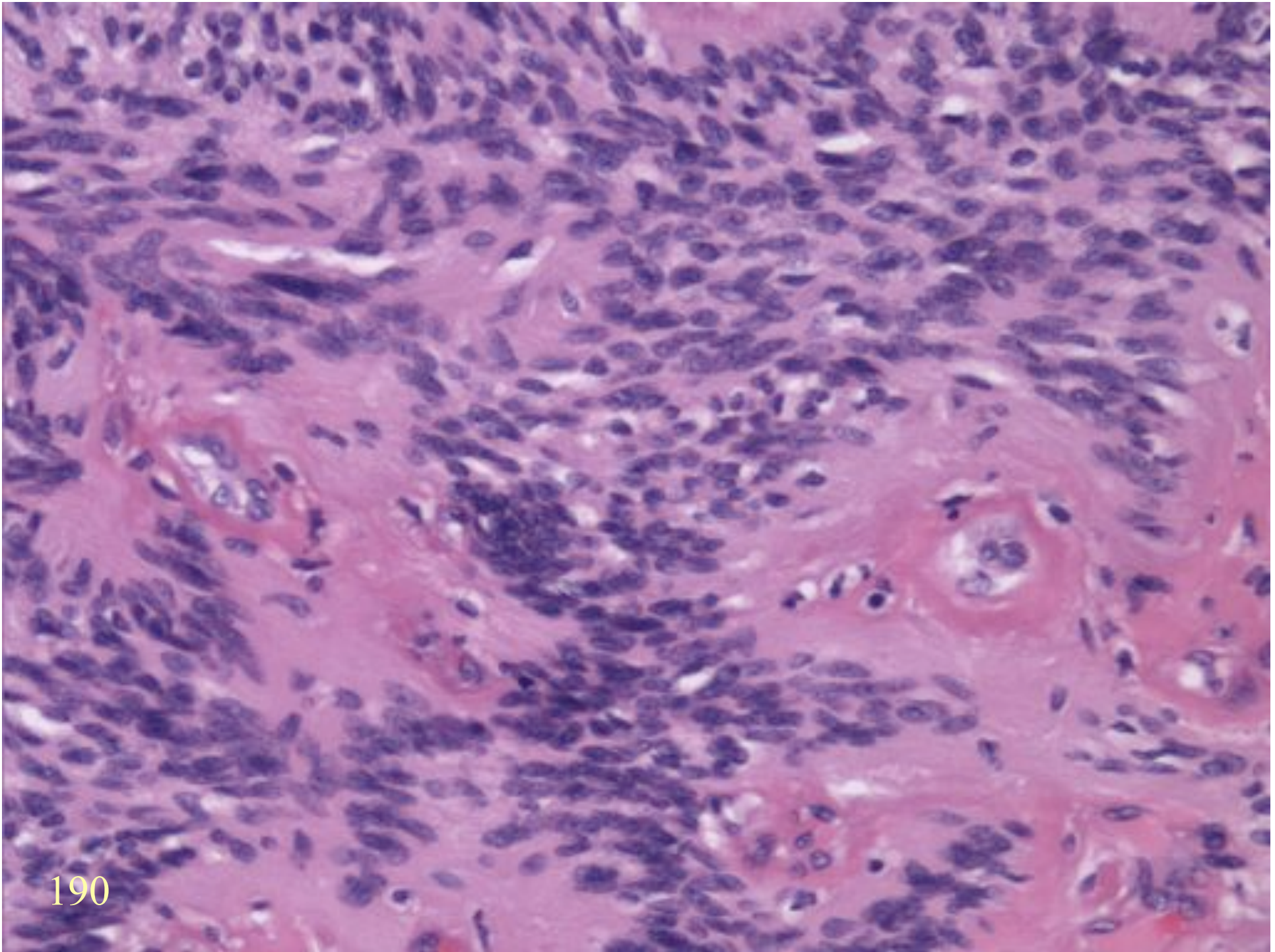
CELLULAR SCHWANNOMA

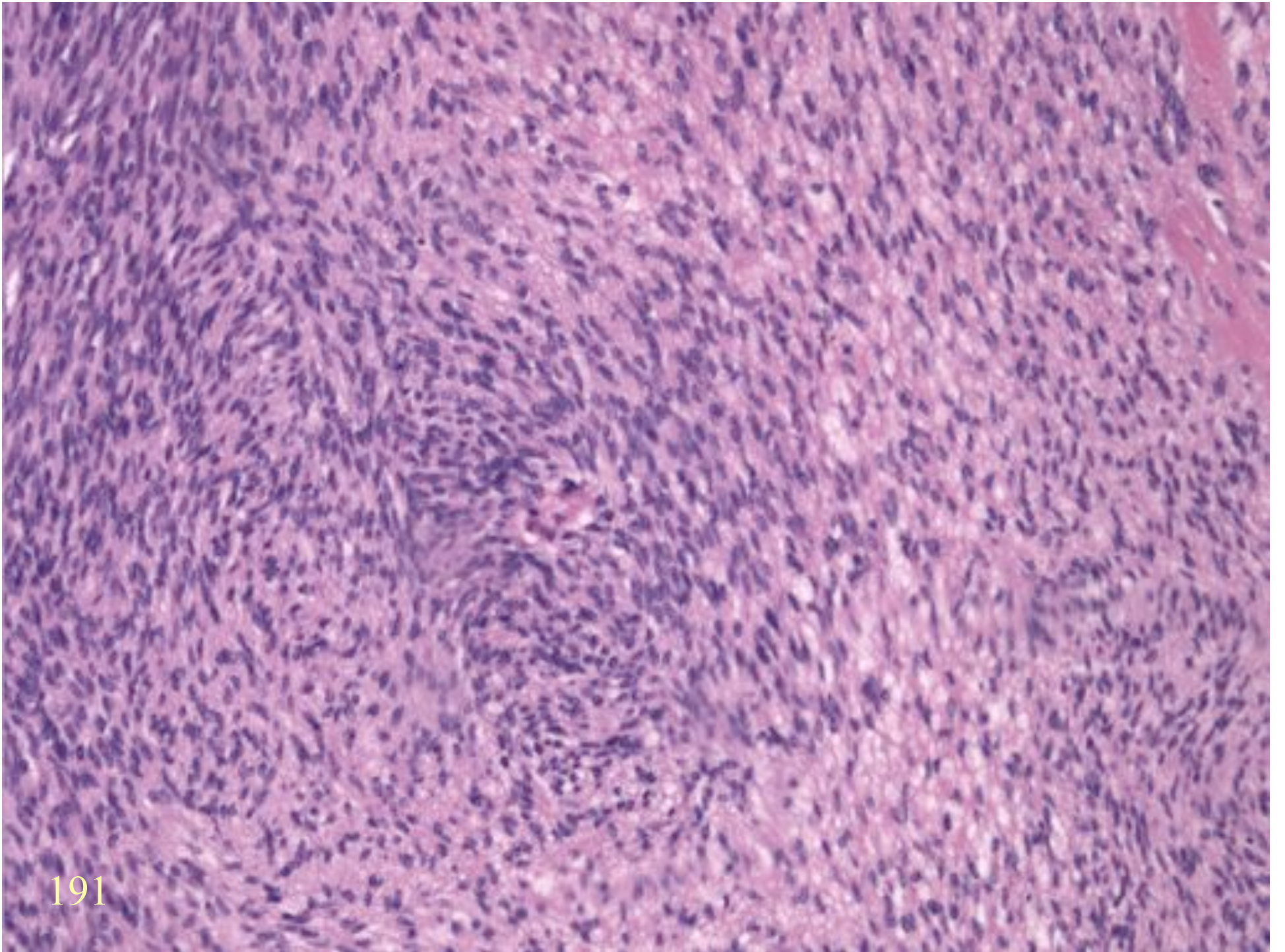
- Deep (para-vertebral)
- Cellular
- Lacks Antoni A / B demarcation
- Mitoses
- Necrosis
- Erodes bone



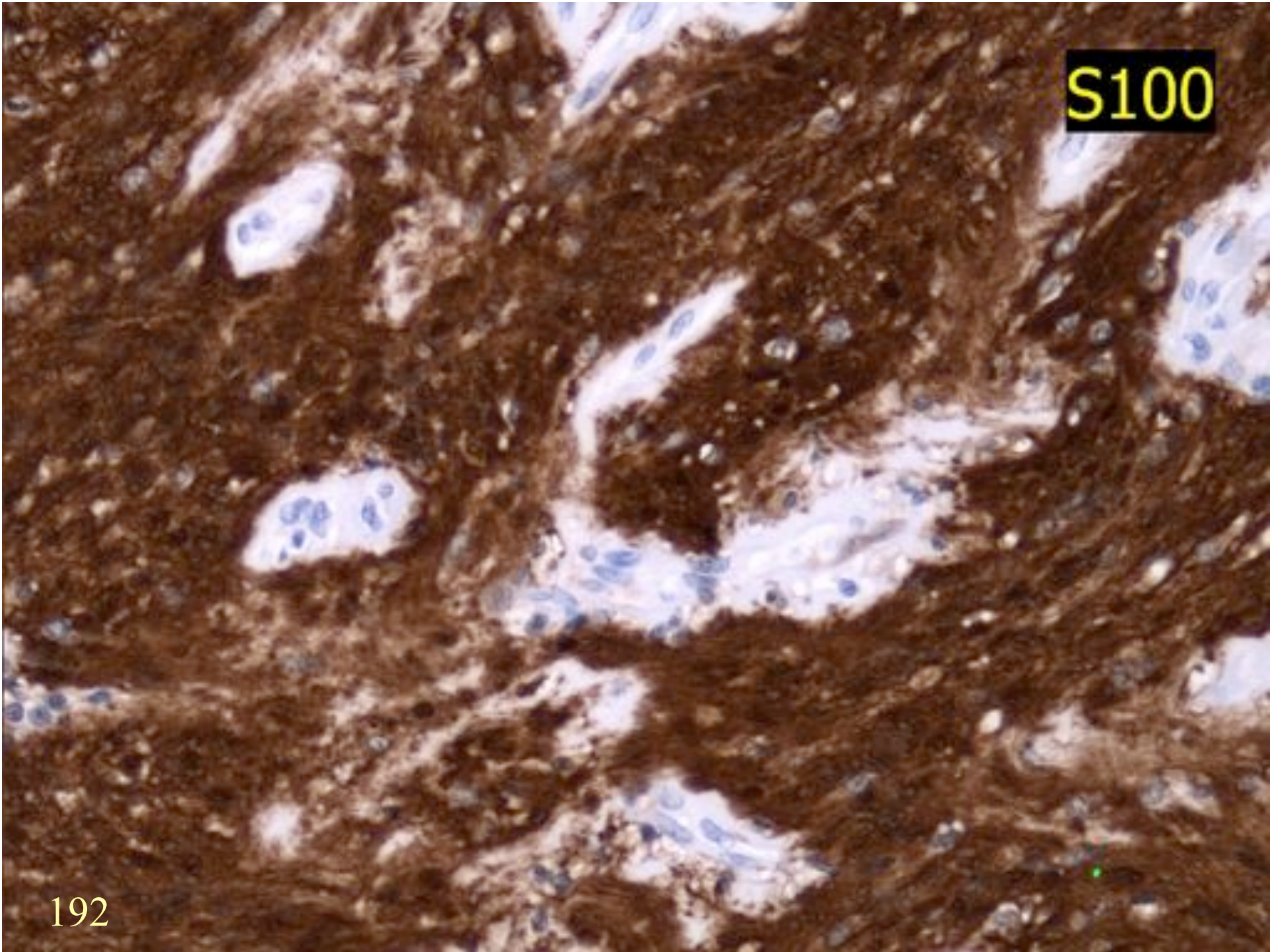




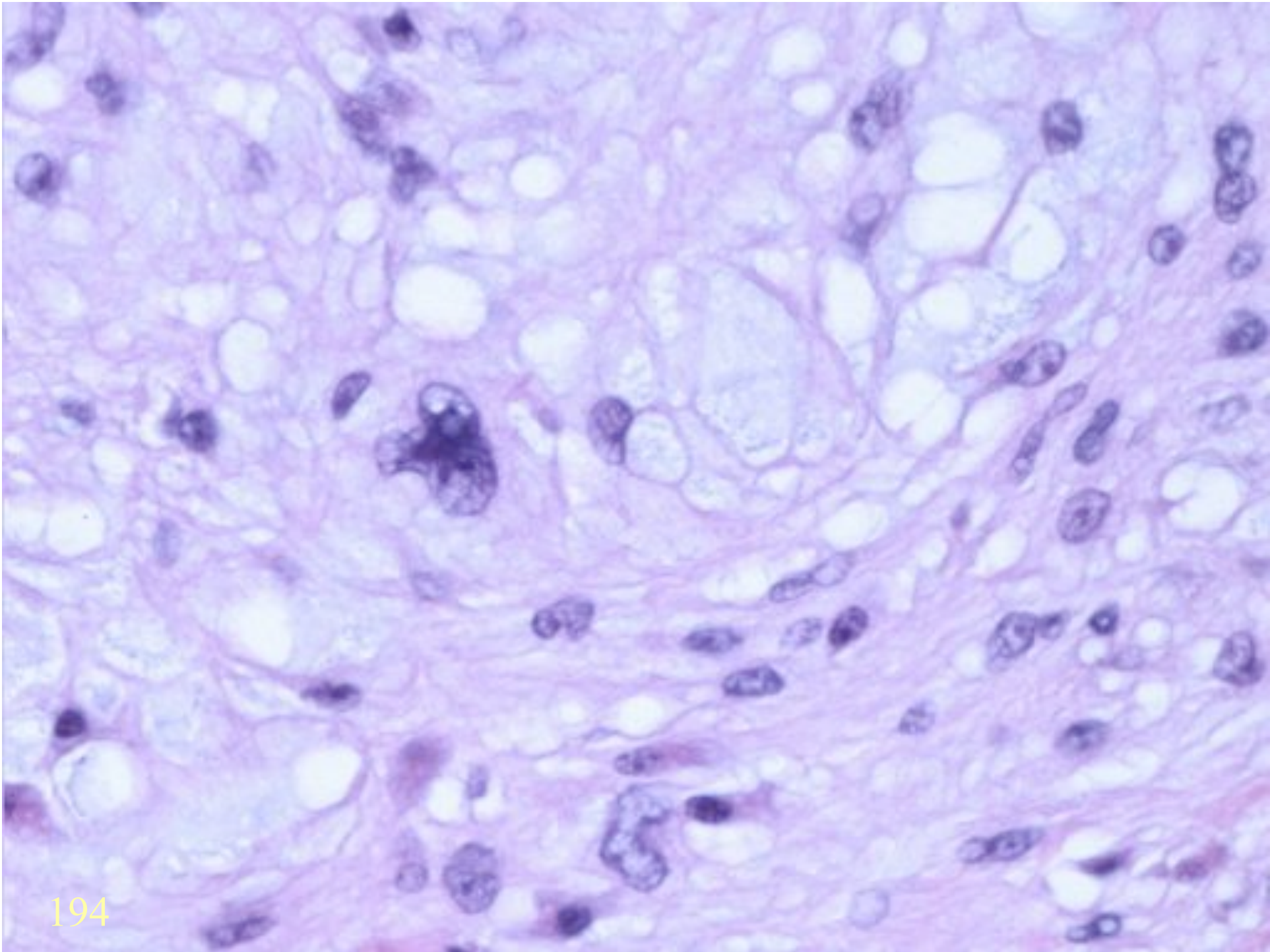




S100

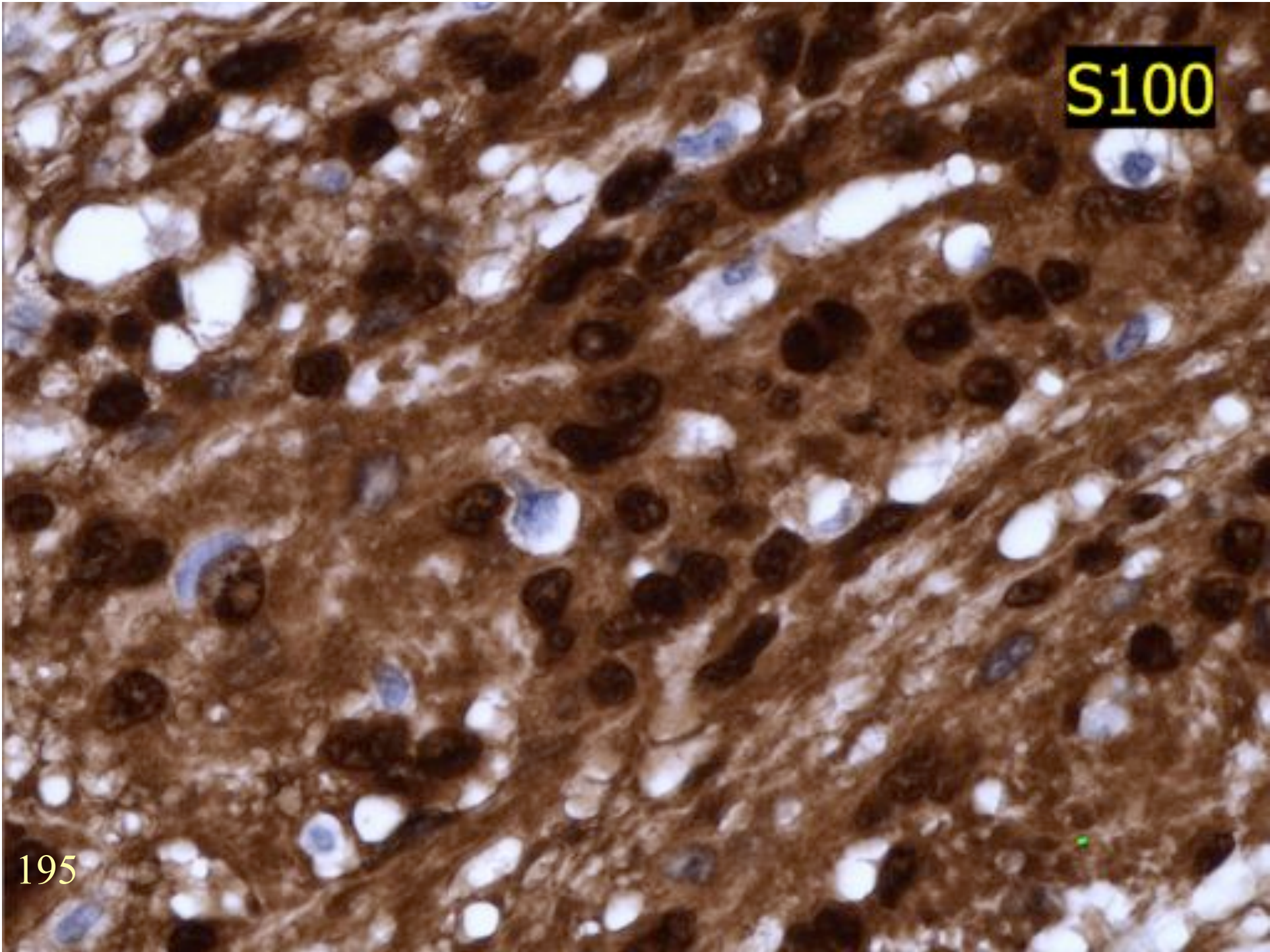


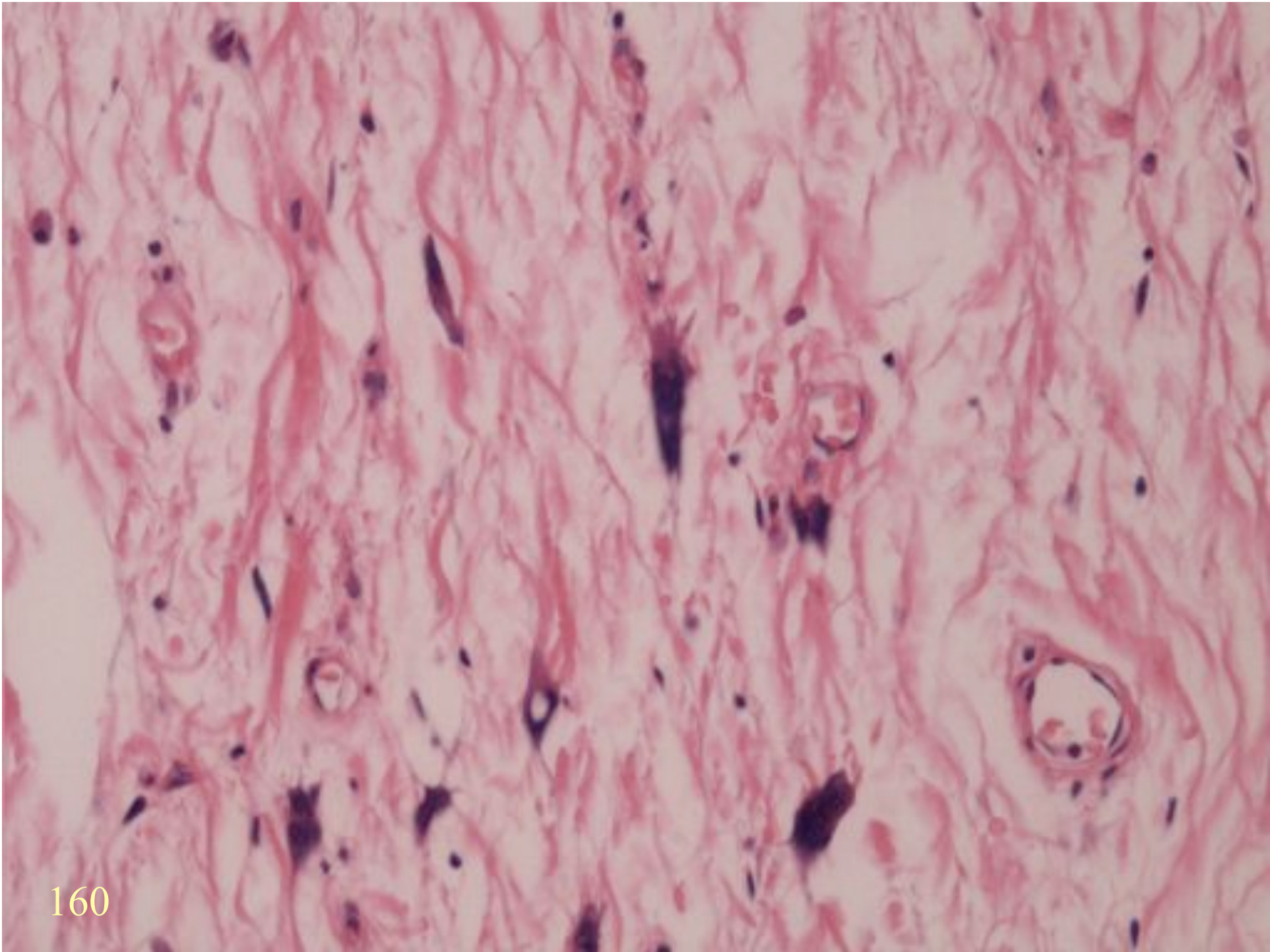
ANCIENT SCHWANNOMA



S100

195





PERIPHERAL NERVE SHEATH SUMMARY

- Cellular Schwannoma
- Ancient Schwannoma
- Diffuse neurofibroma