

6 High Grade NHL

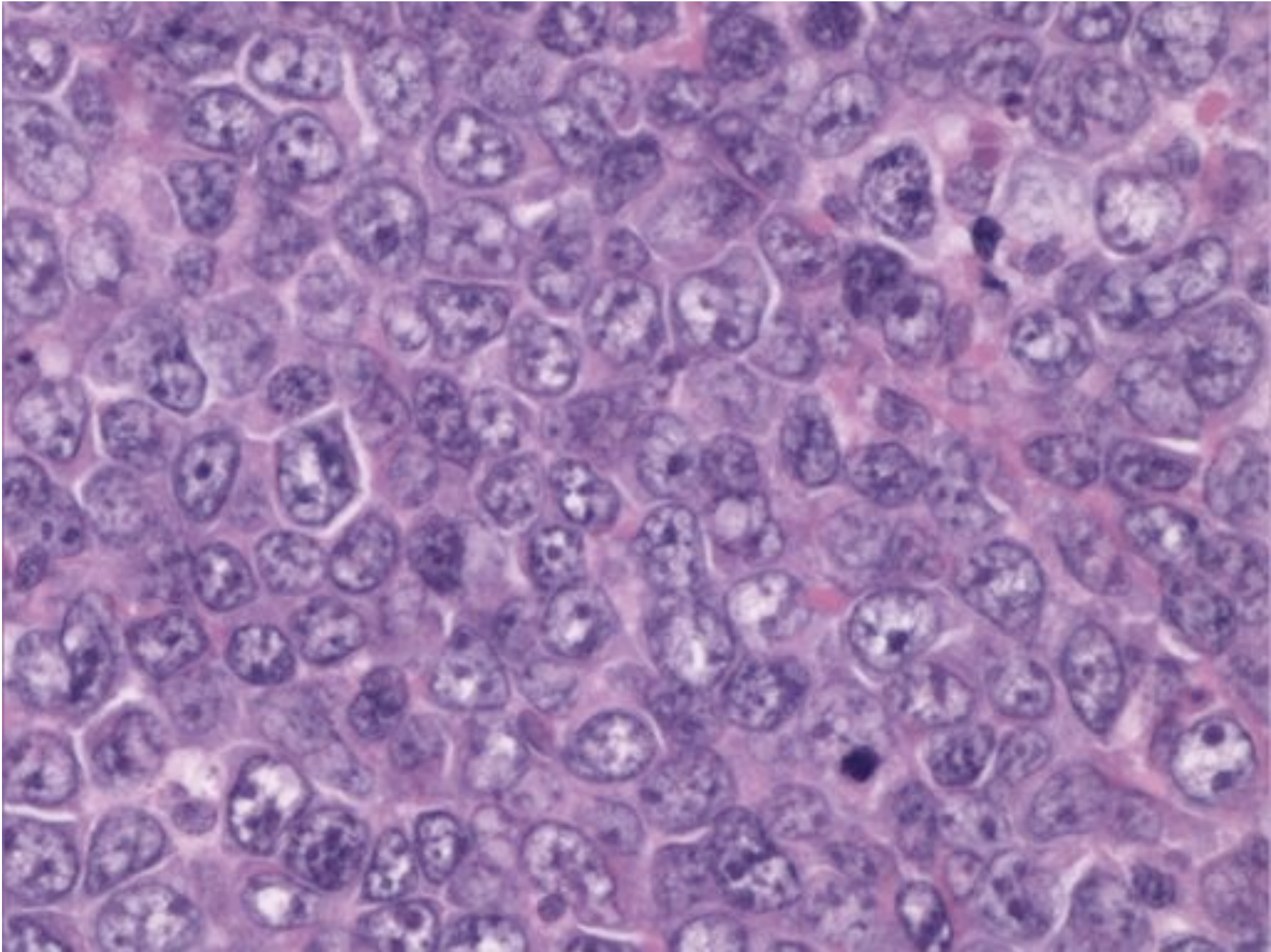
Mark Smith

Bristol Lymphoma Day

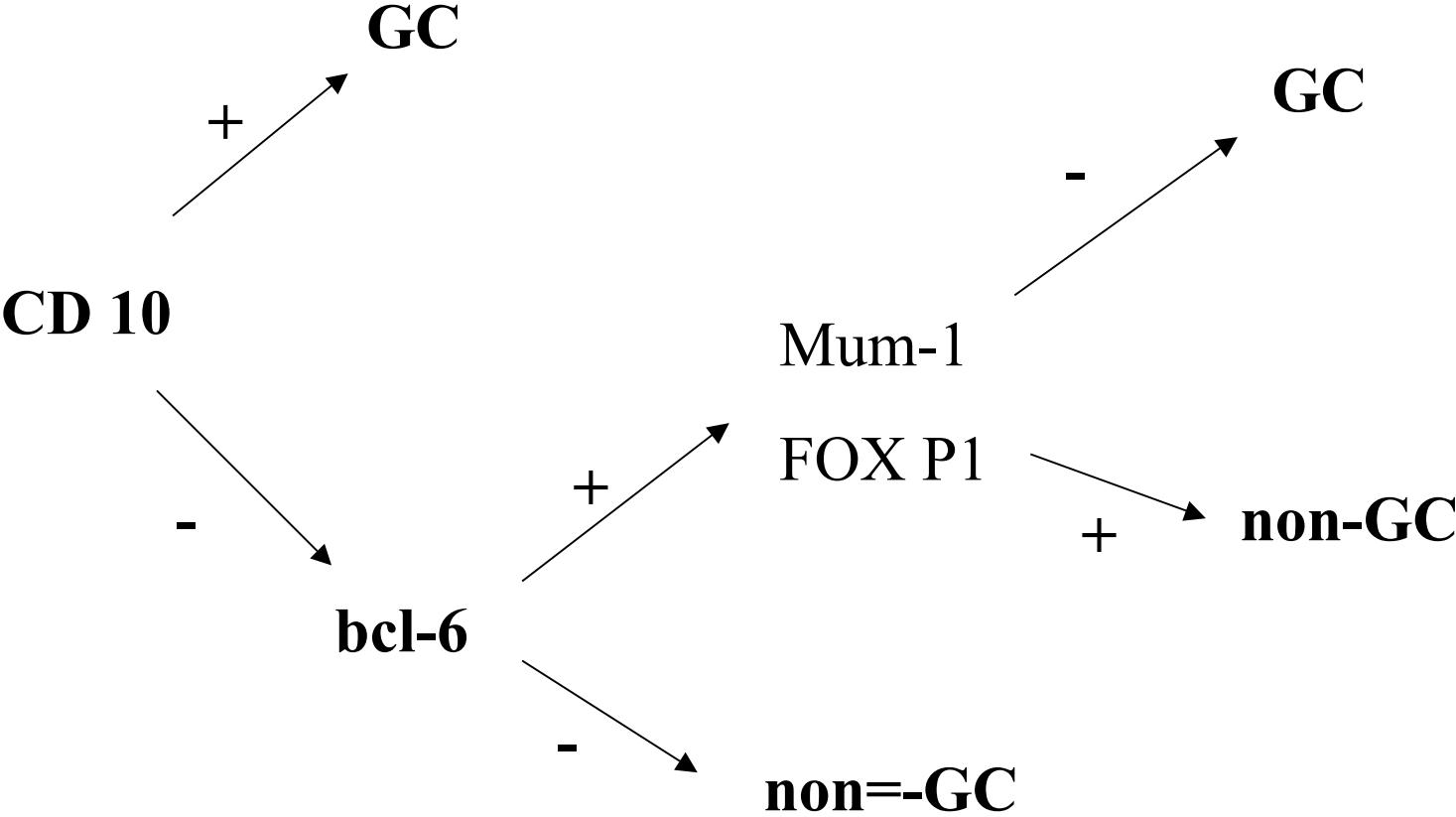
High-grade B-cell Lymphoma

- Diffuse large B-cell lymphoma
- Burkitt lymphoma
- Precursor B-lymphoblastic lymphoma

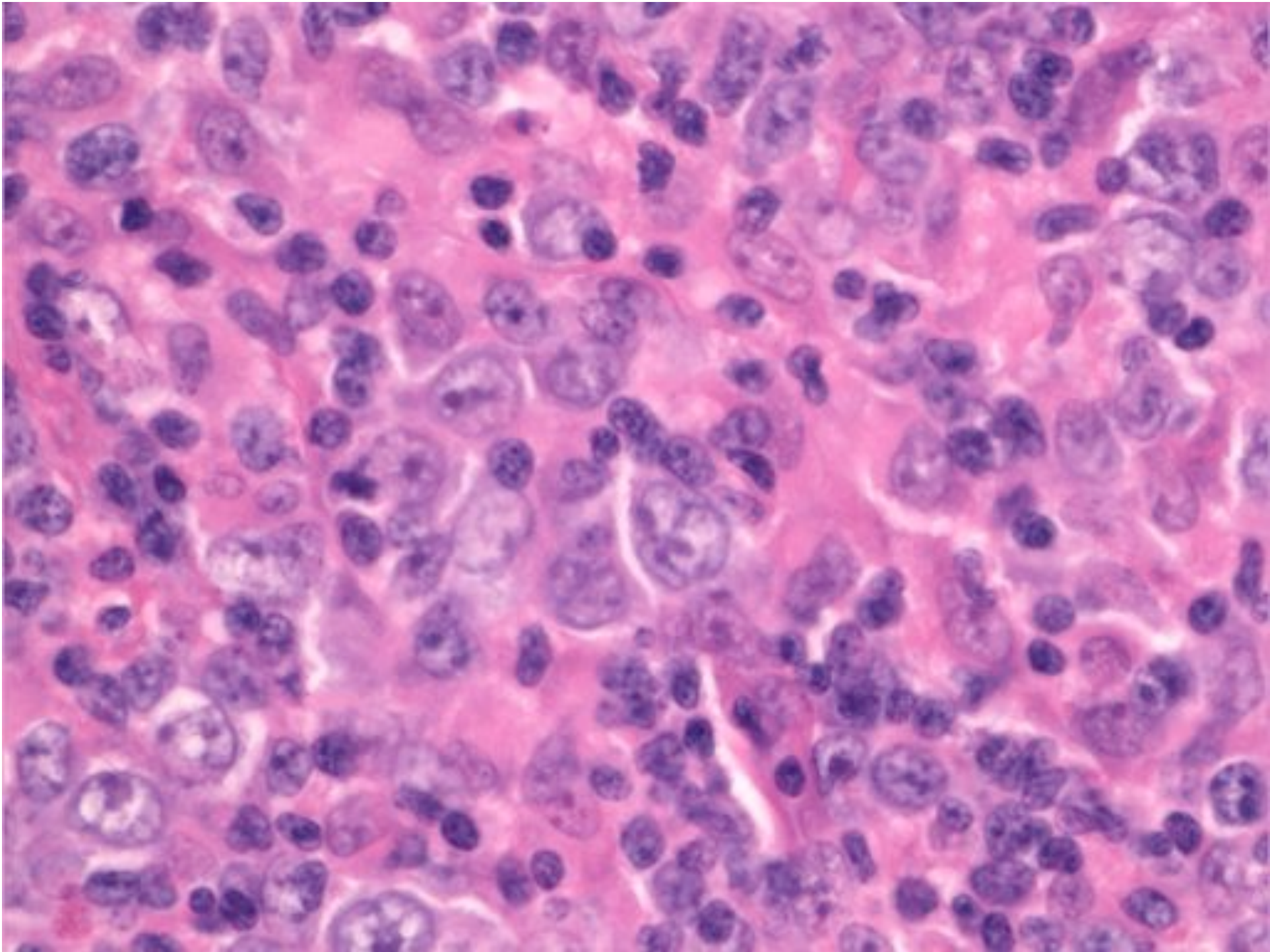
Diffuse Large B-cell Lymphoma



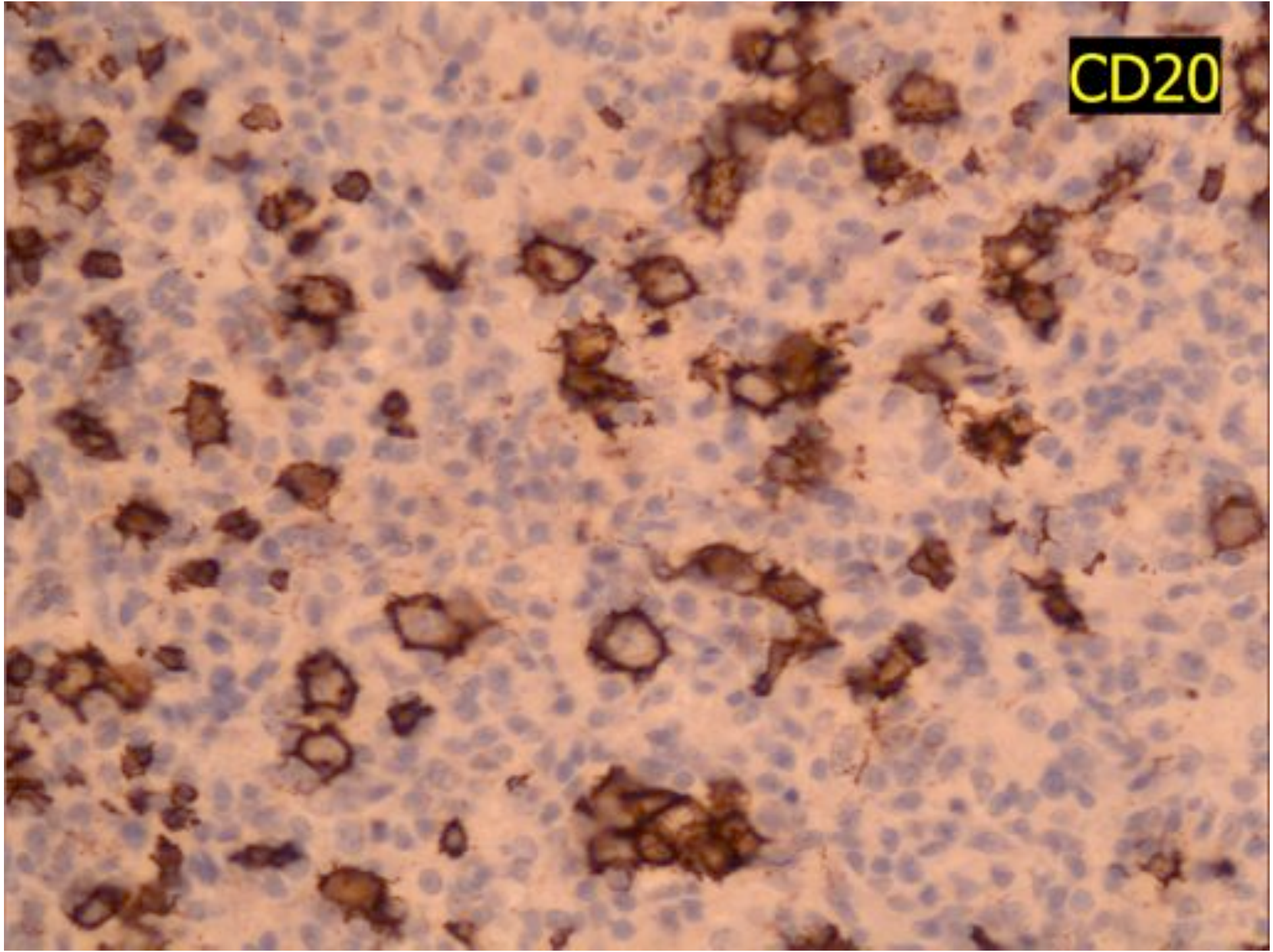
GC vs non-GC Activated Phenotype



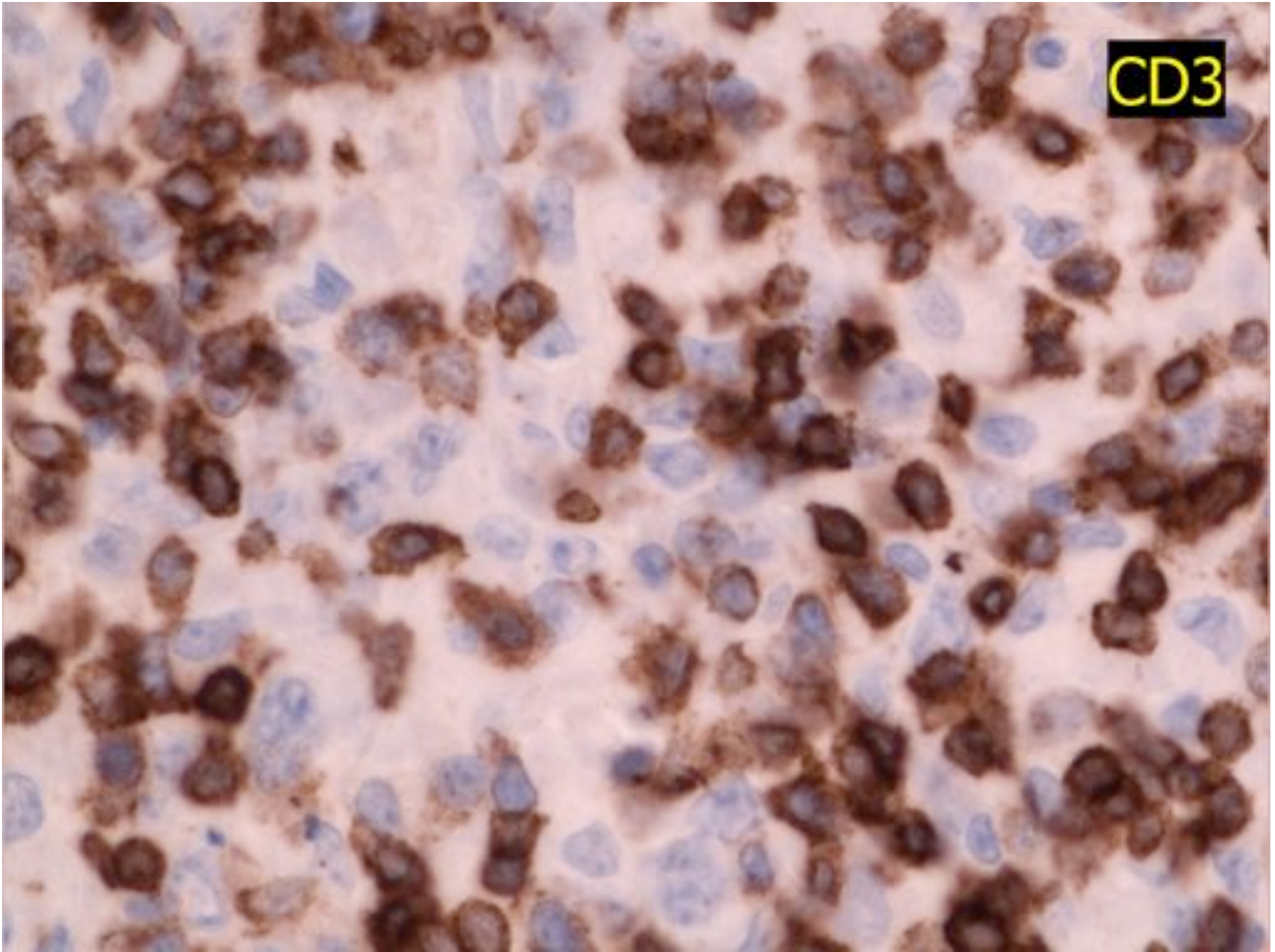
T-cell rich B-cell DLBCL



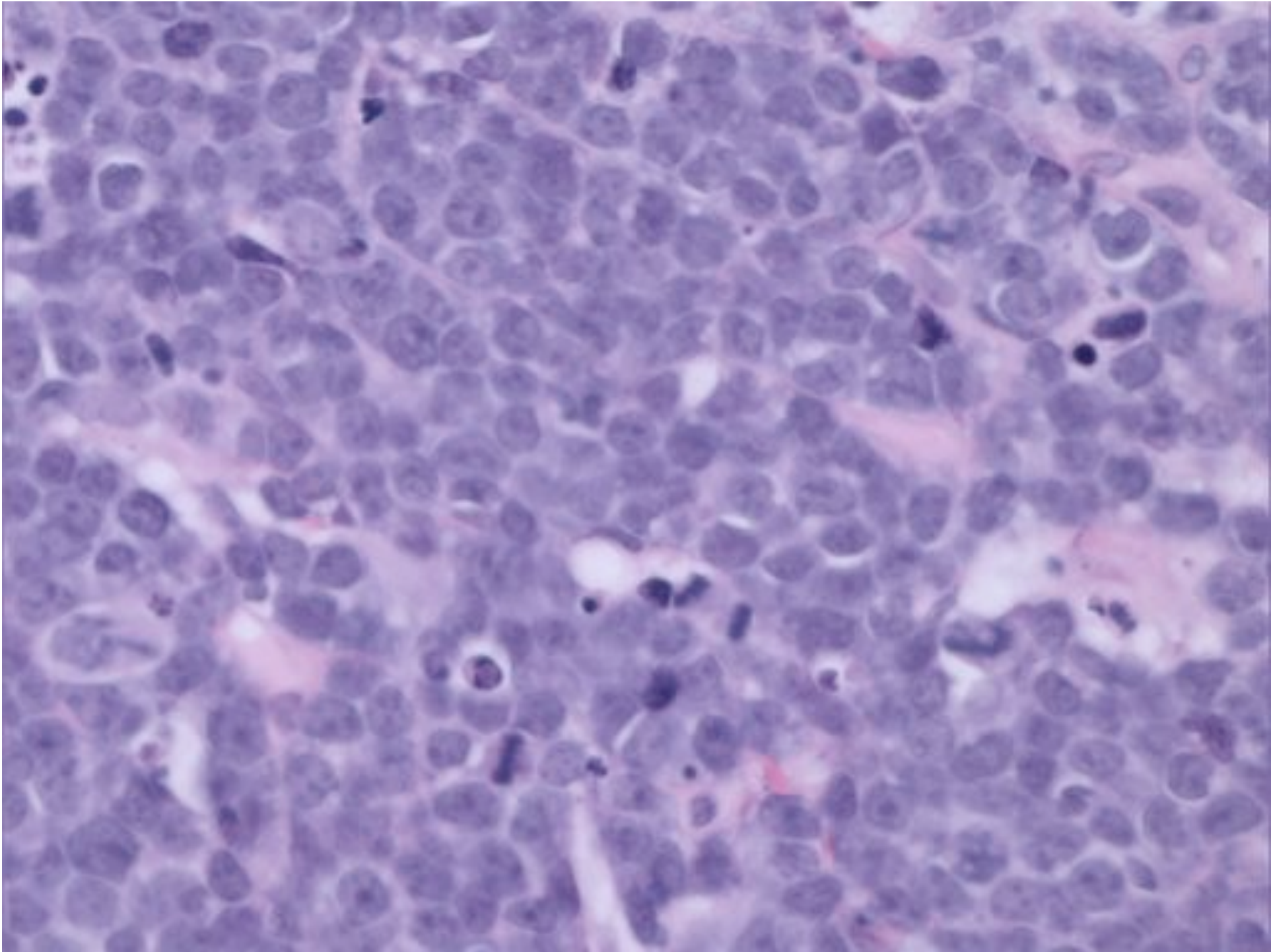
CD20

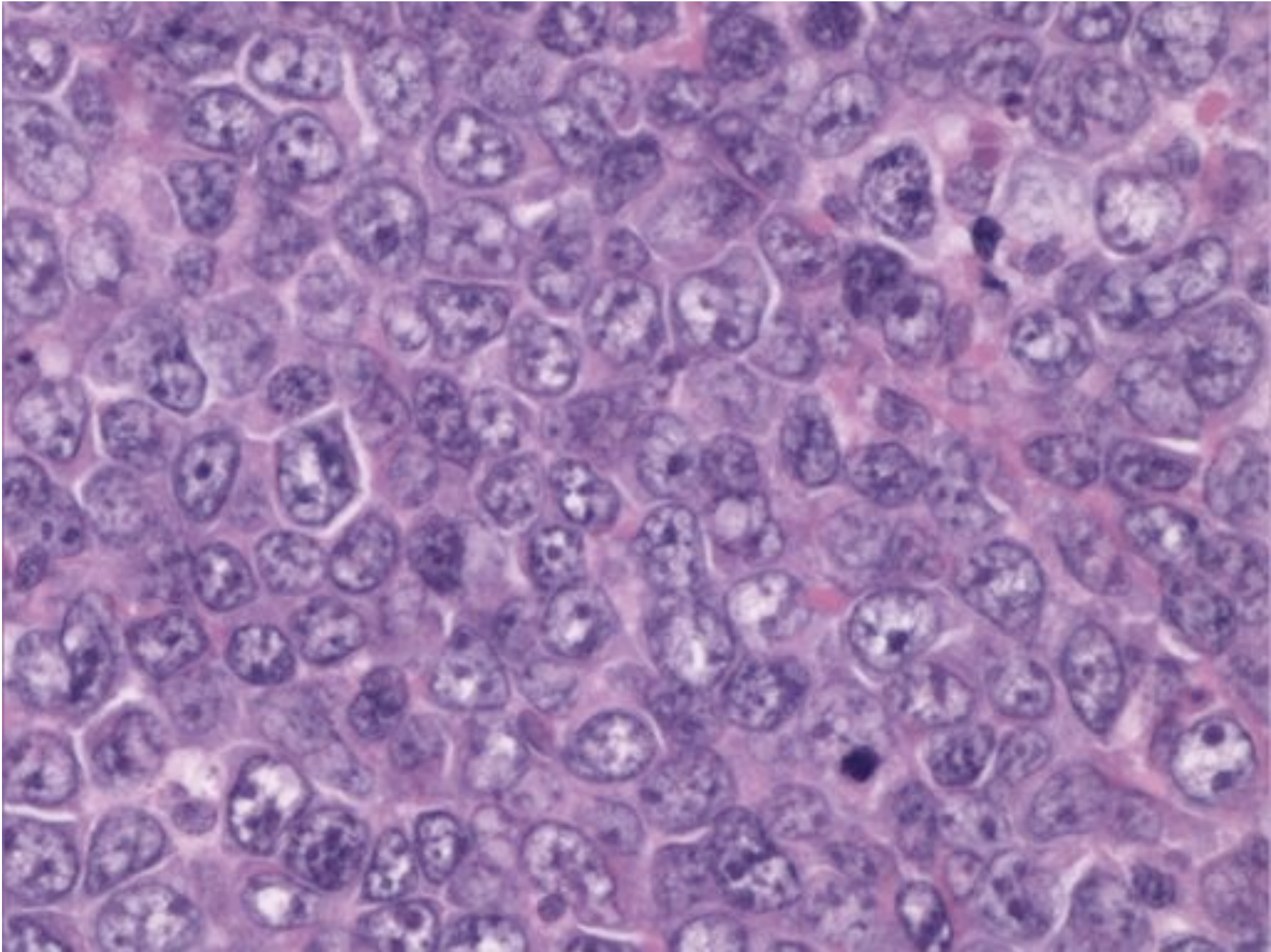


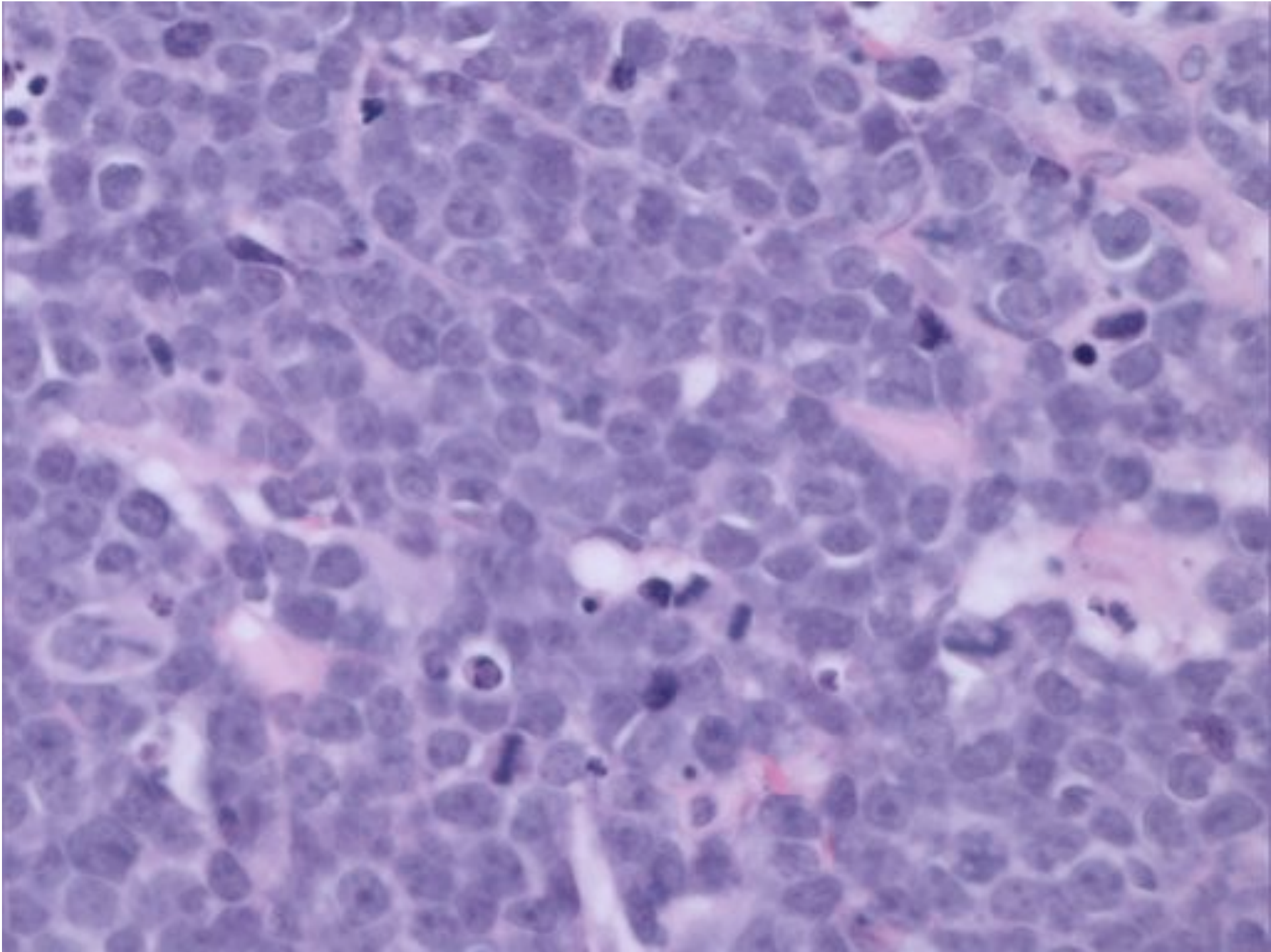
CD3

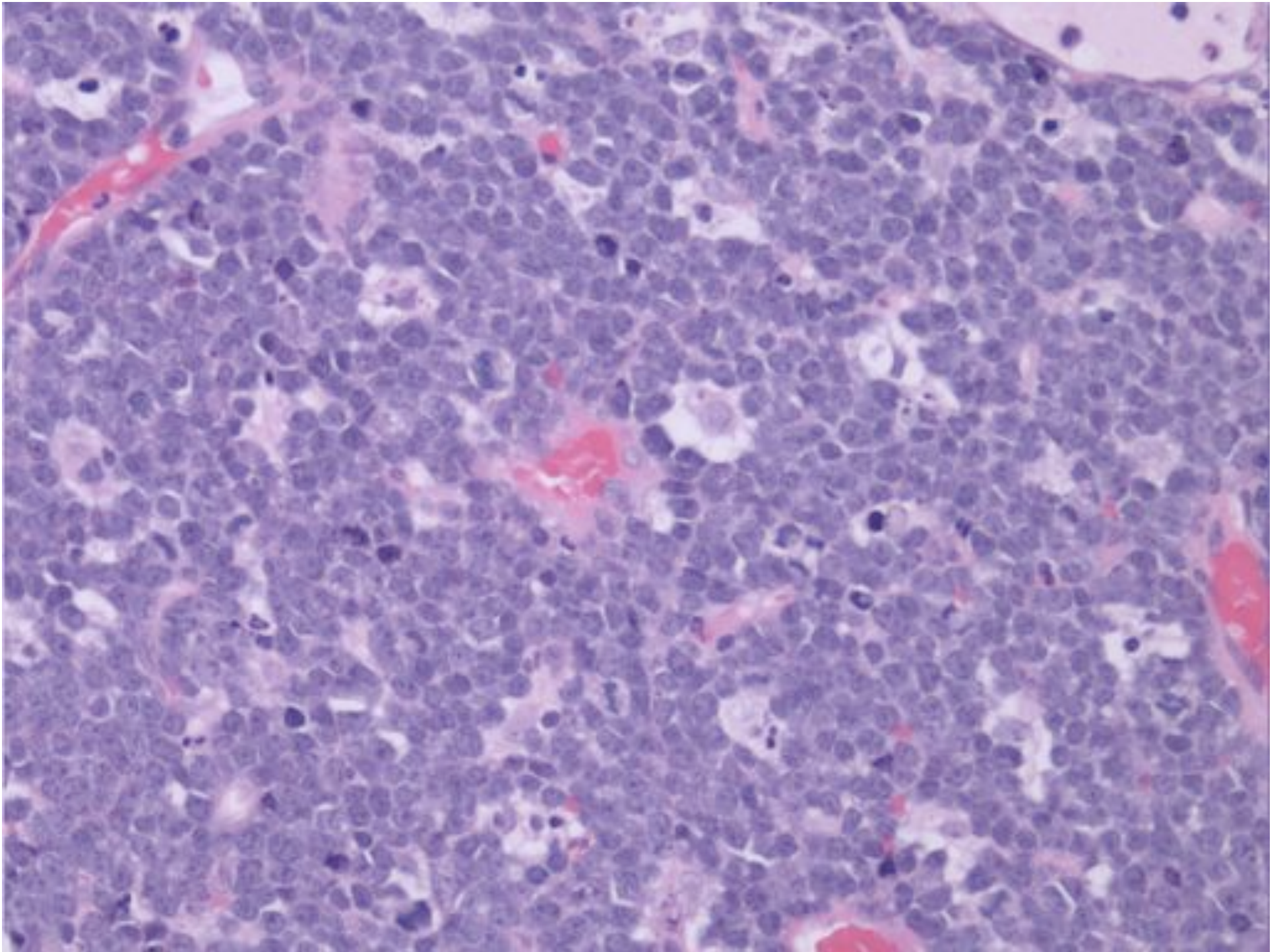


Burkitt Lymphoma

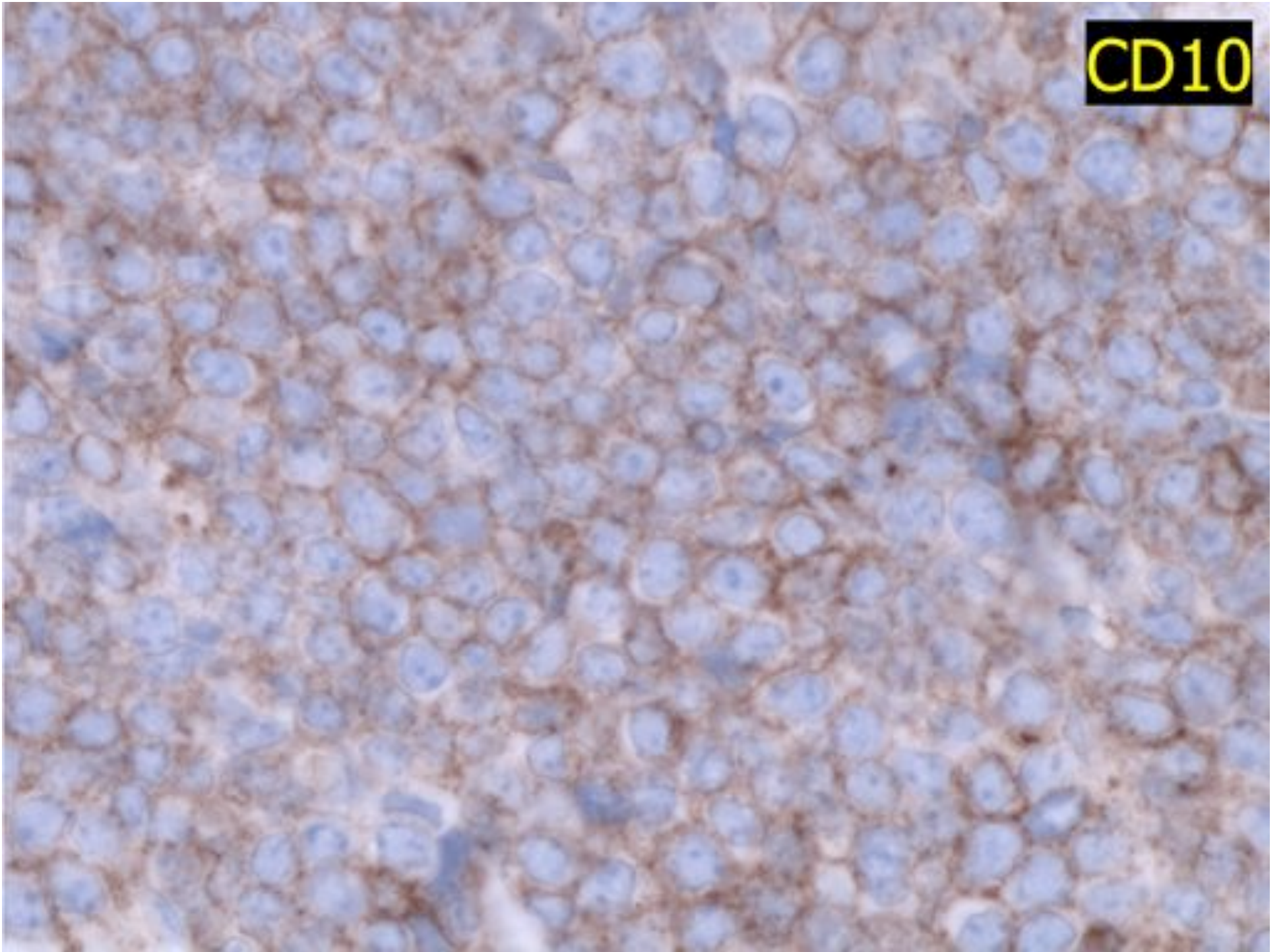




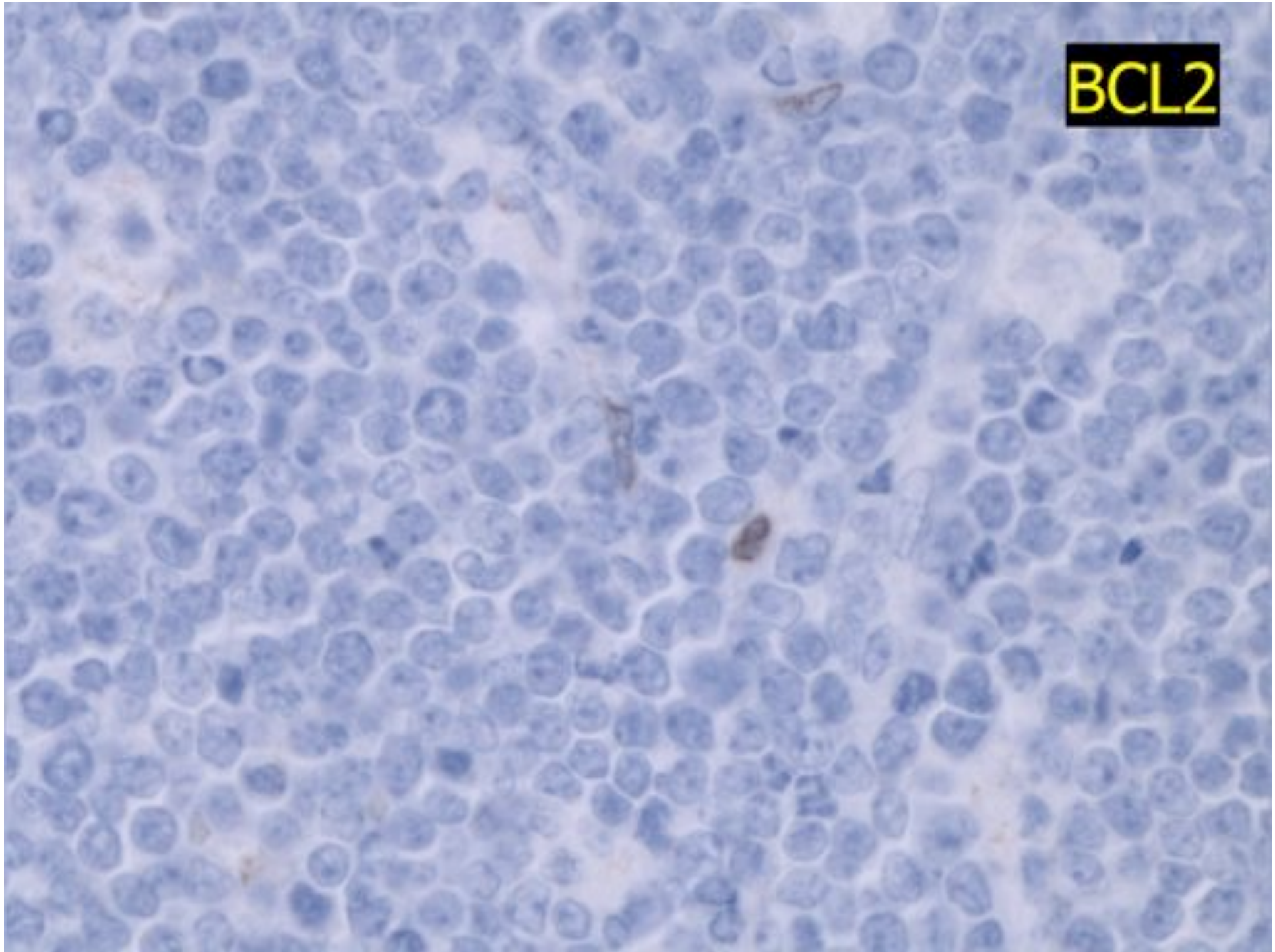




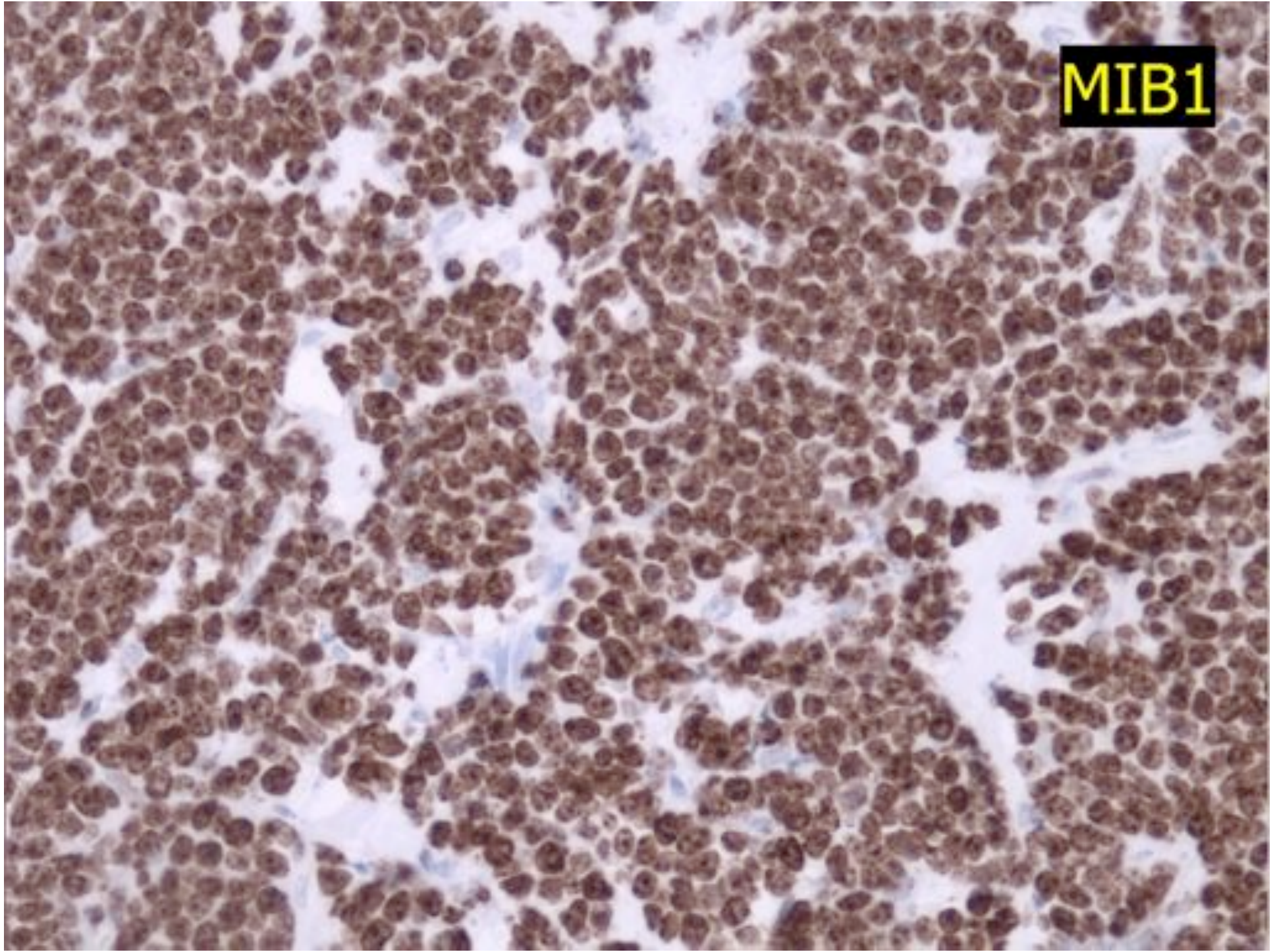
CD10

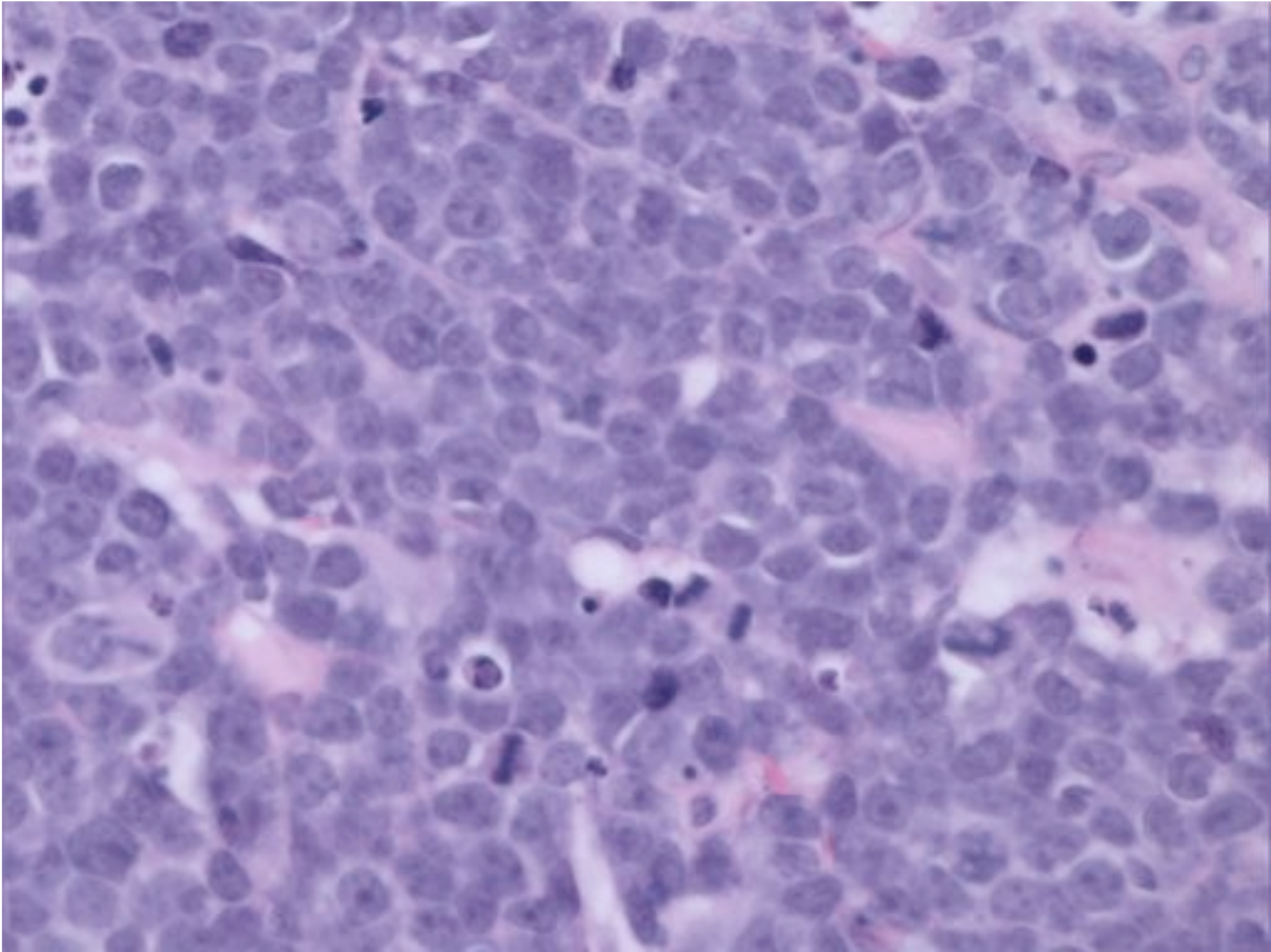


BCL2



MIB1

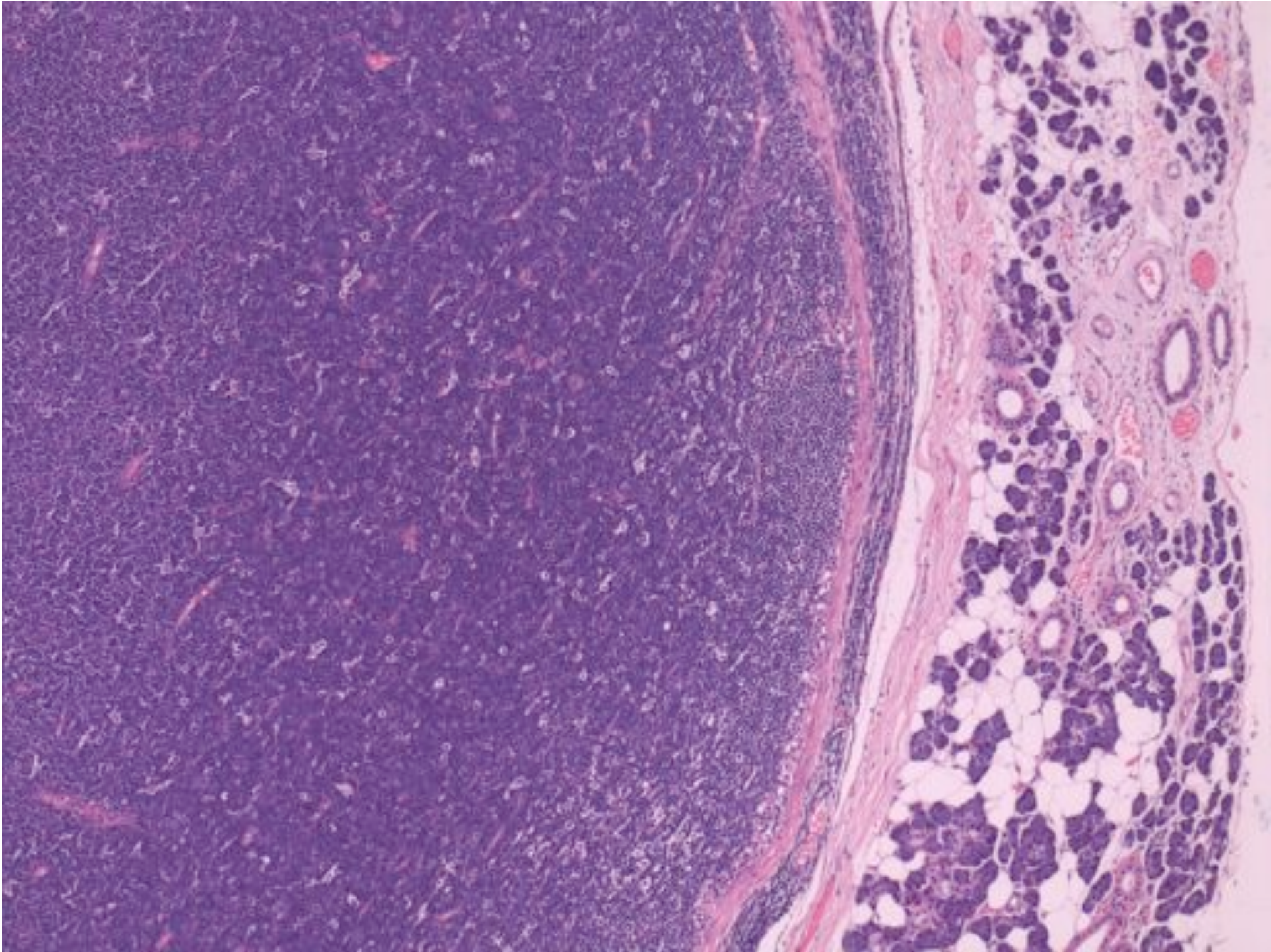


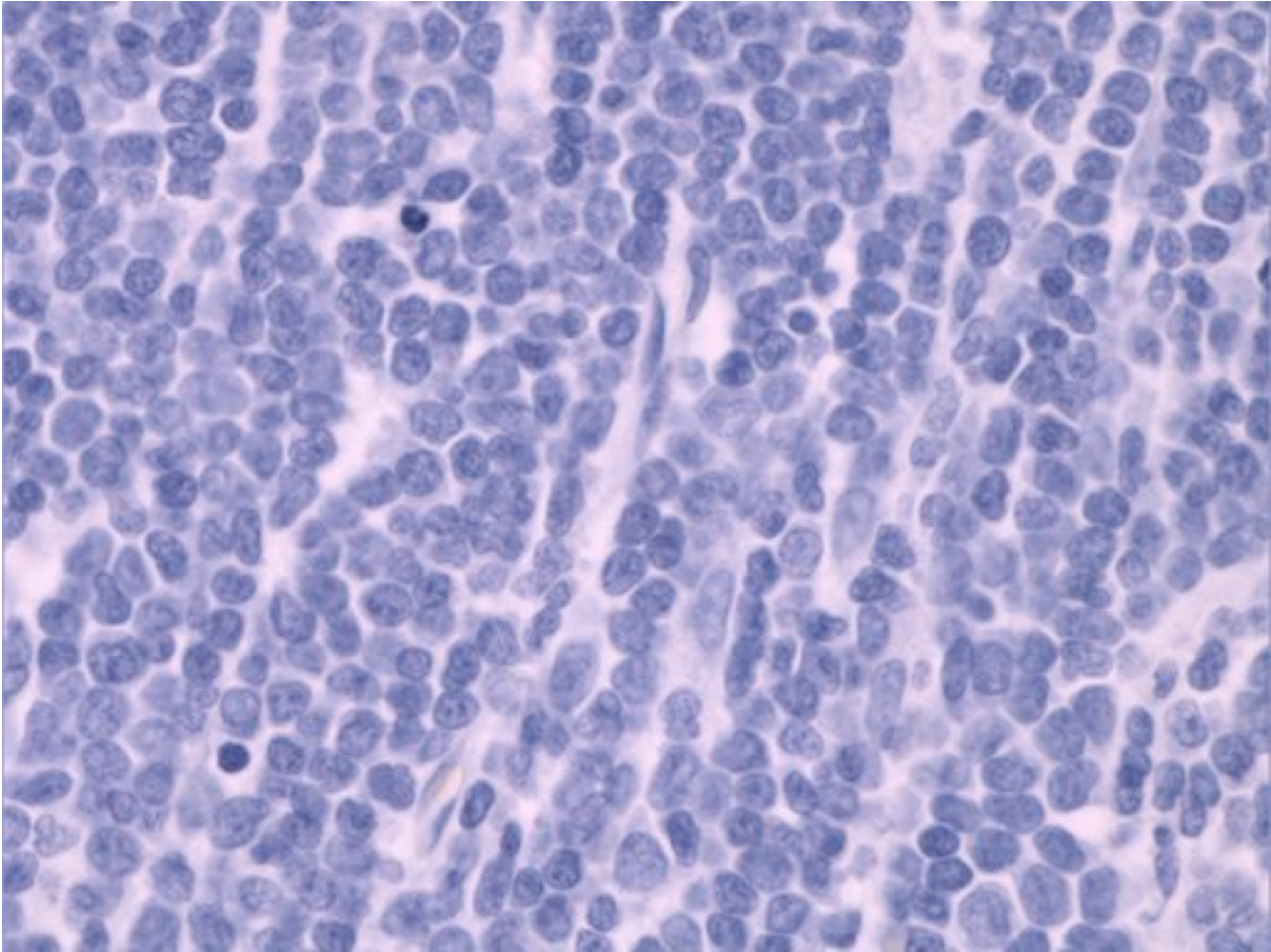


Differential diagnosis of medium-sized haematolymphoid tumours

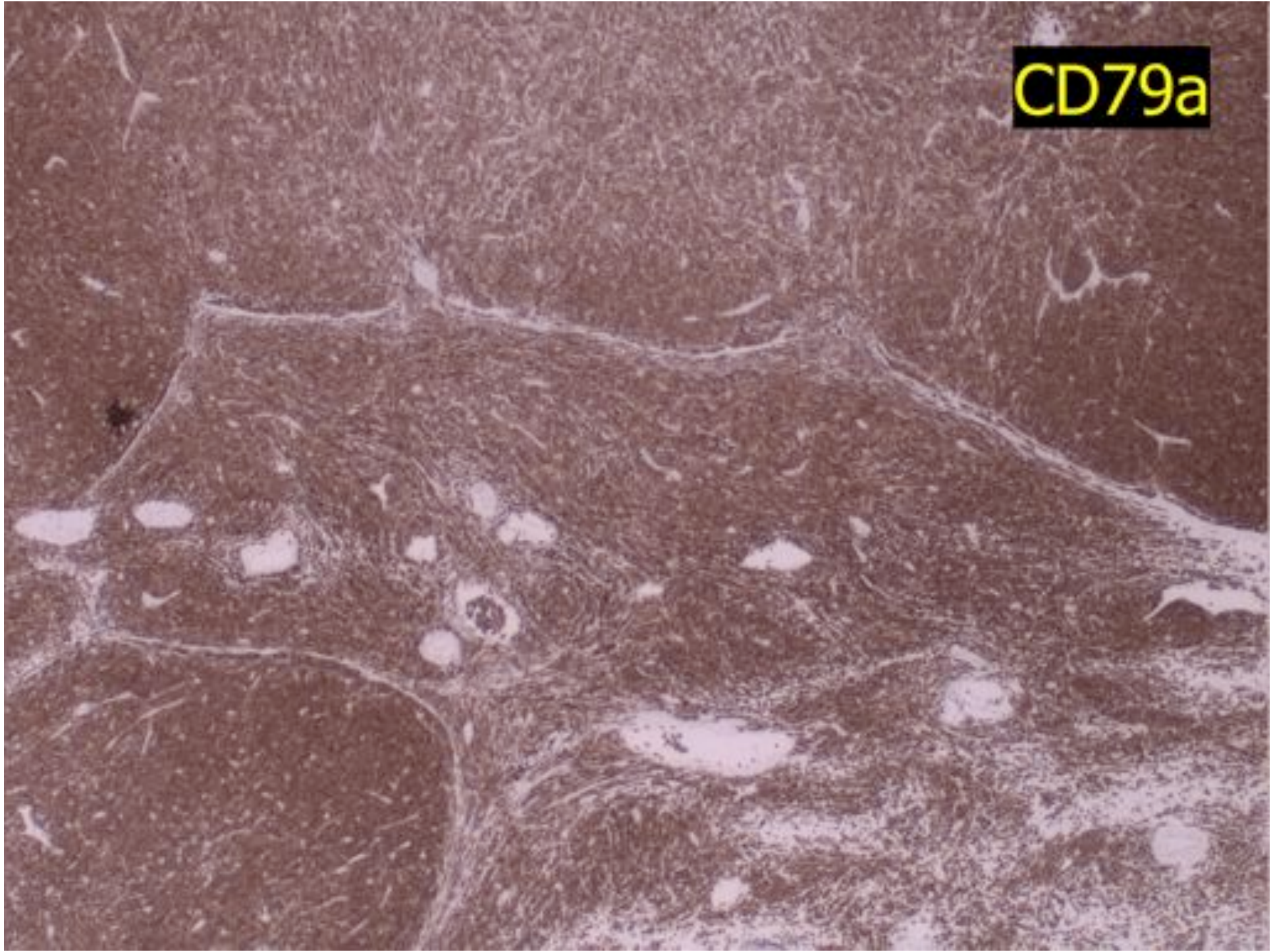
- Lymphoblastic lymphoma
- Burkitt lymphoma
- Blastoid mantle cell lymphoma
- Blastic transformation of other indolent B NHL
- De novo PTCL
- Blastic NK cell lymphoma (now haematodermic tumour)

Precursor B-cell Lymphoblastic Lymphoma

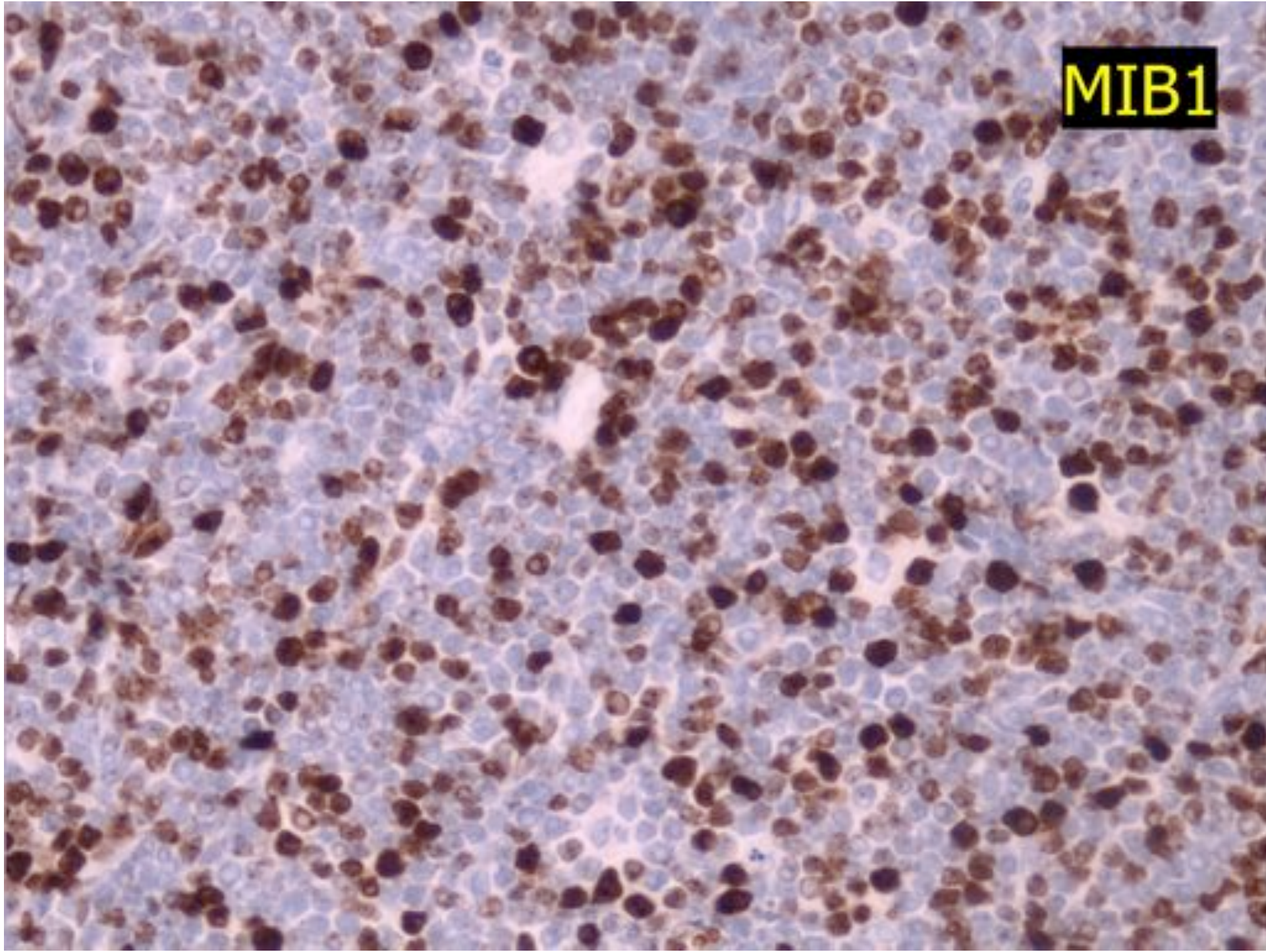




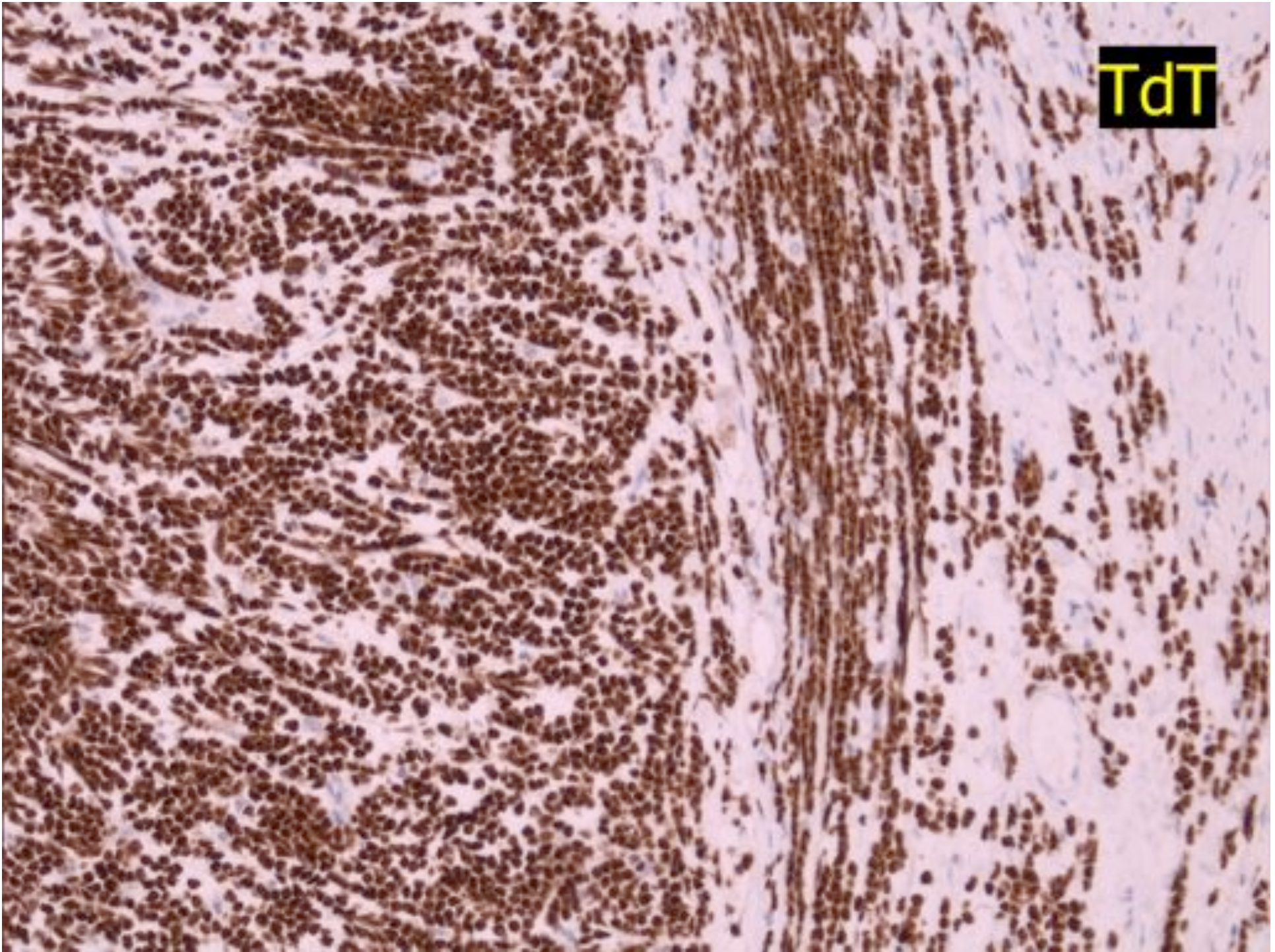
CD79a



MIB1



TdT



Differential diagnosis of TdT expression

- Lymphoblastic T or B
- Haematodermic tumour (previously blastic NK cell lymphoma)
- Granulocytic sarcoma/AML
- Thymus/thymoma