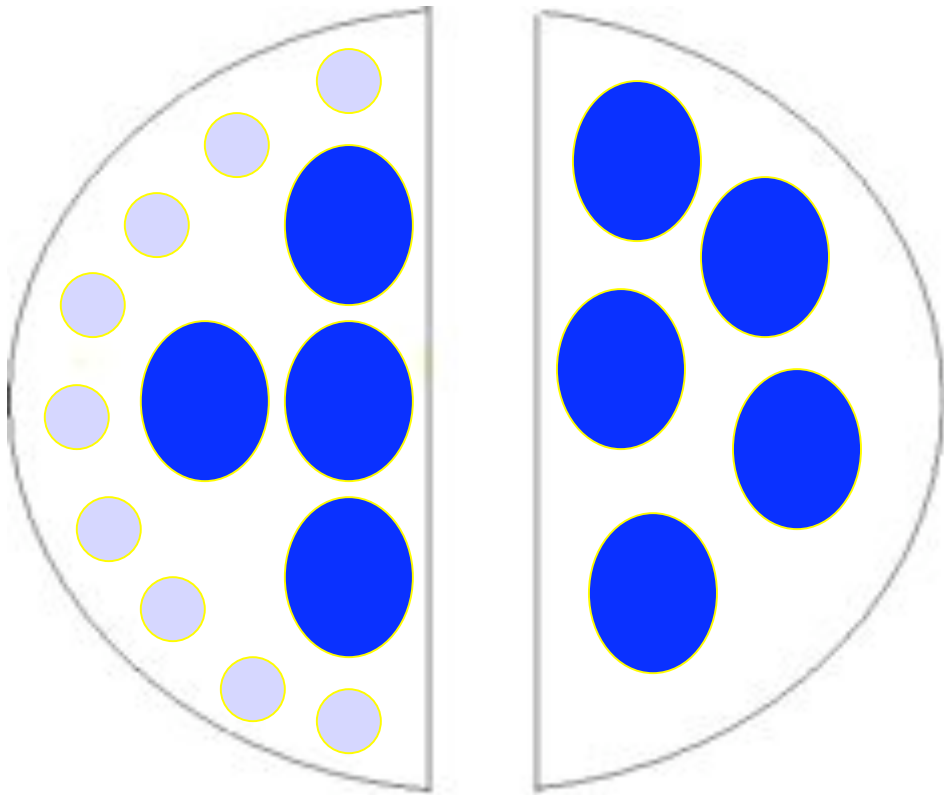
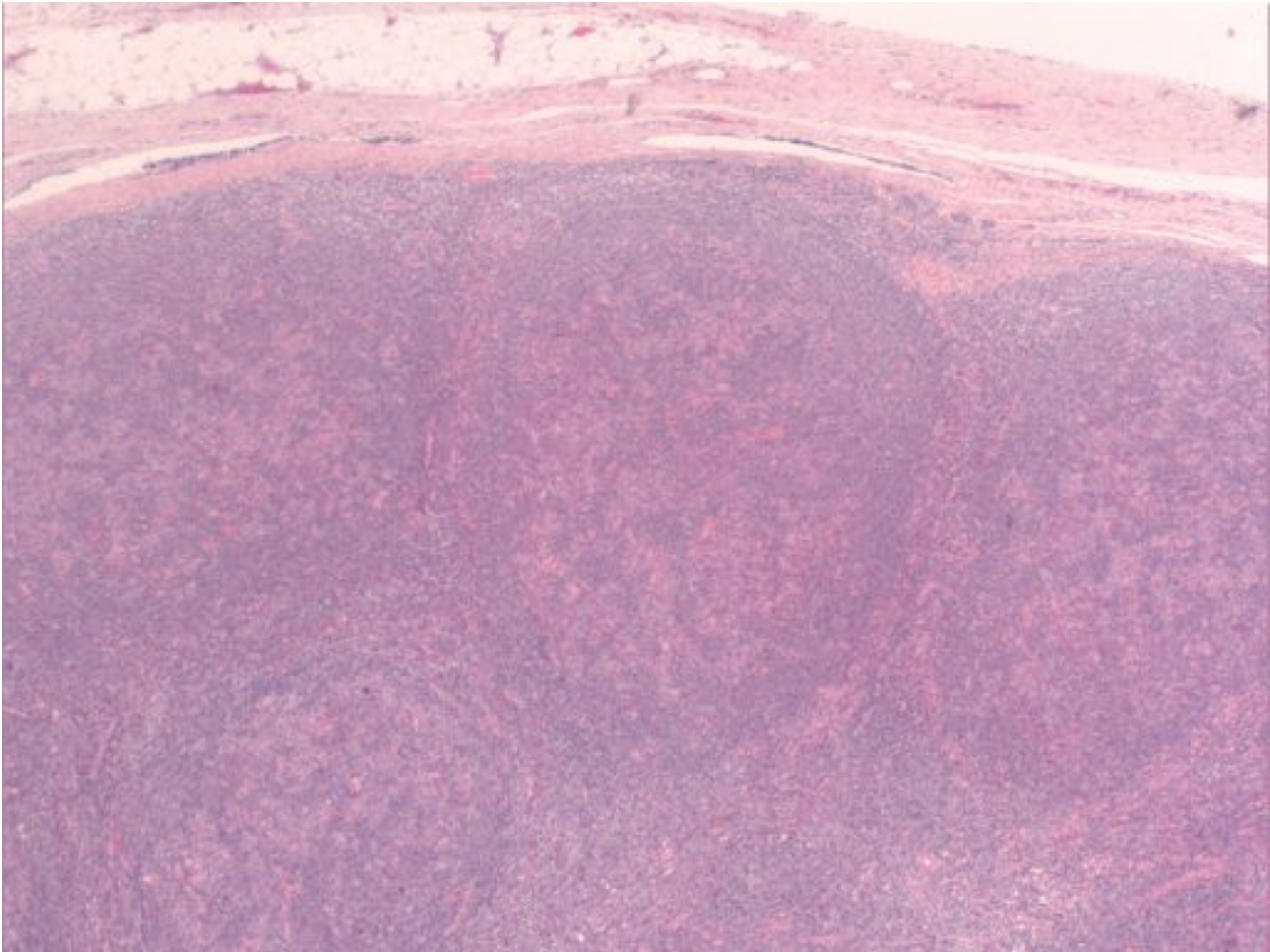


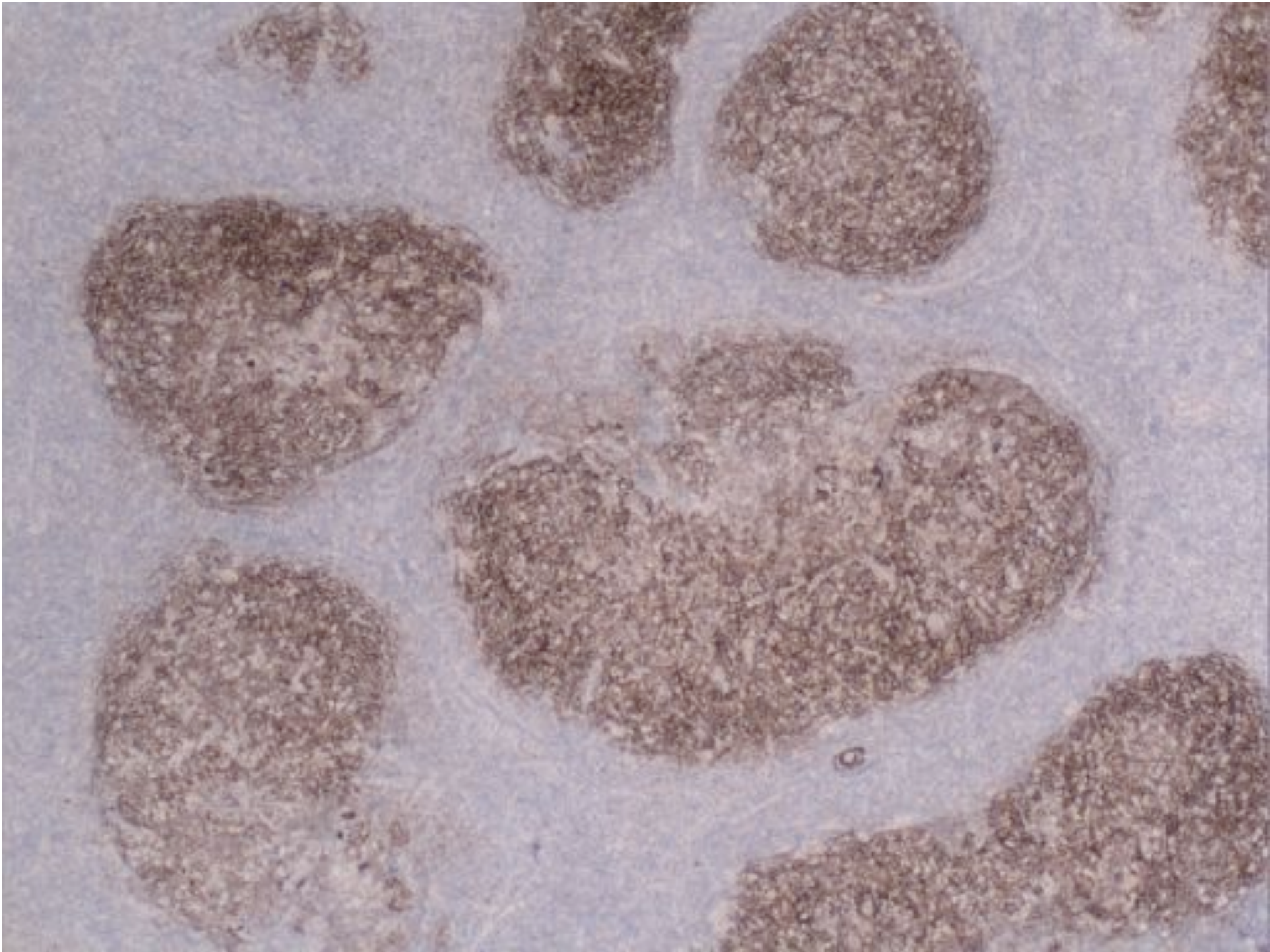
Nodular lymphocyte predominant Hodgkin lymphoma

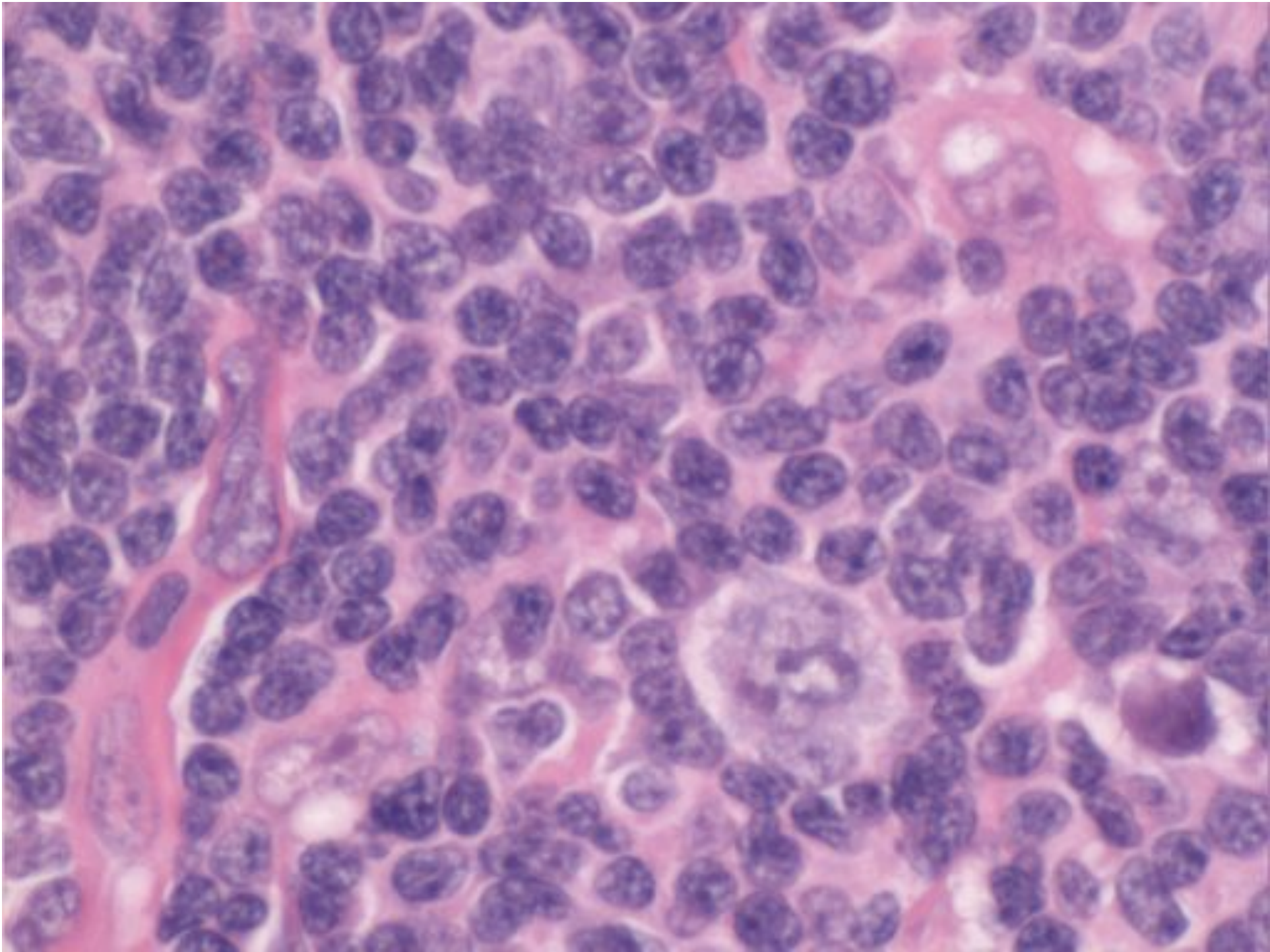
- Male
- Peak in 4th decade
- Commonly enlarged cervical or axillary nodes
- Commonly Stage I or II
- Frequently recurrent
- Rarely fatal
- Up to 5% develop DLBCL

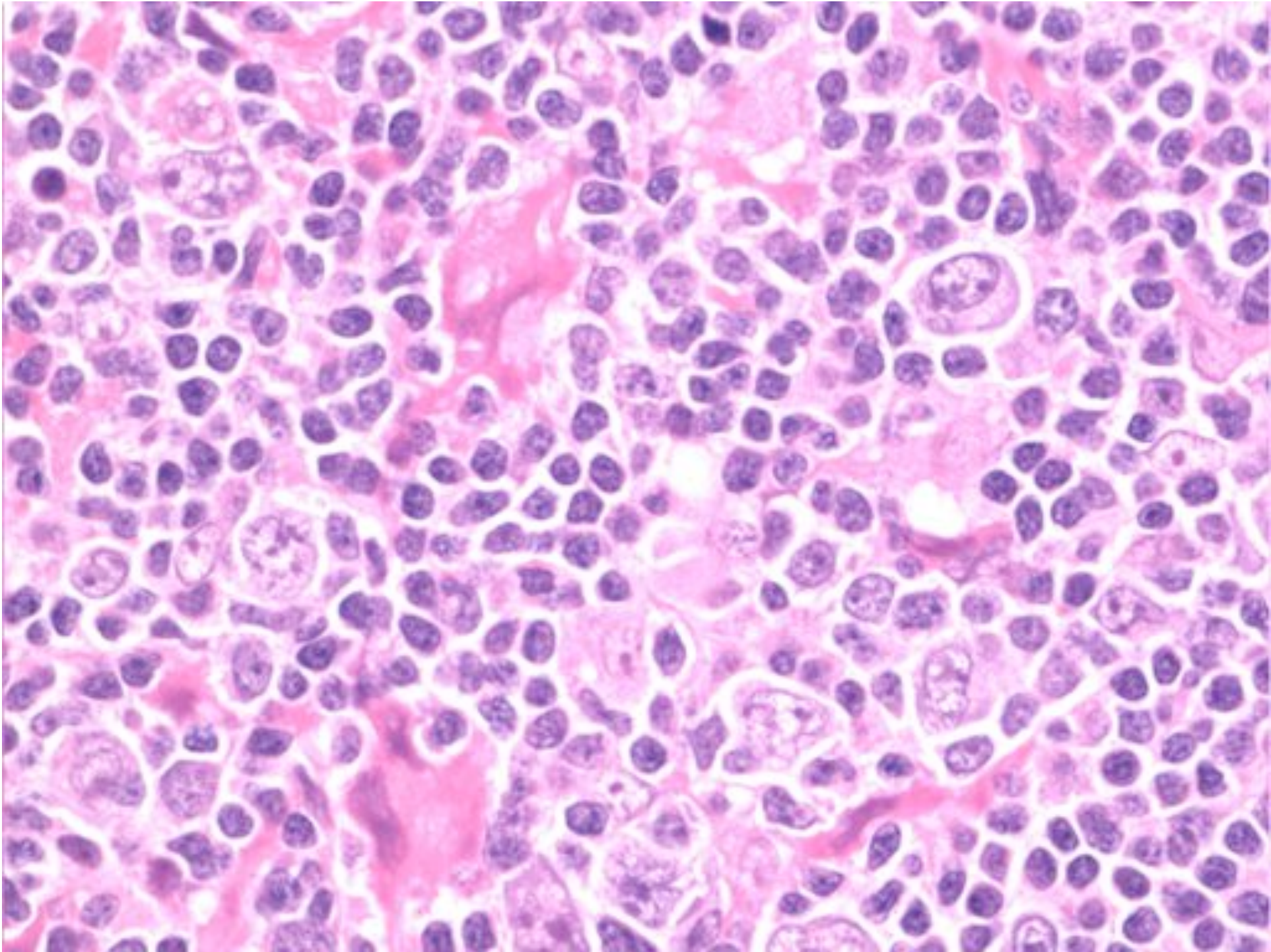
NLPHL







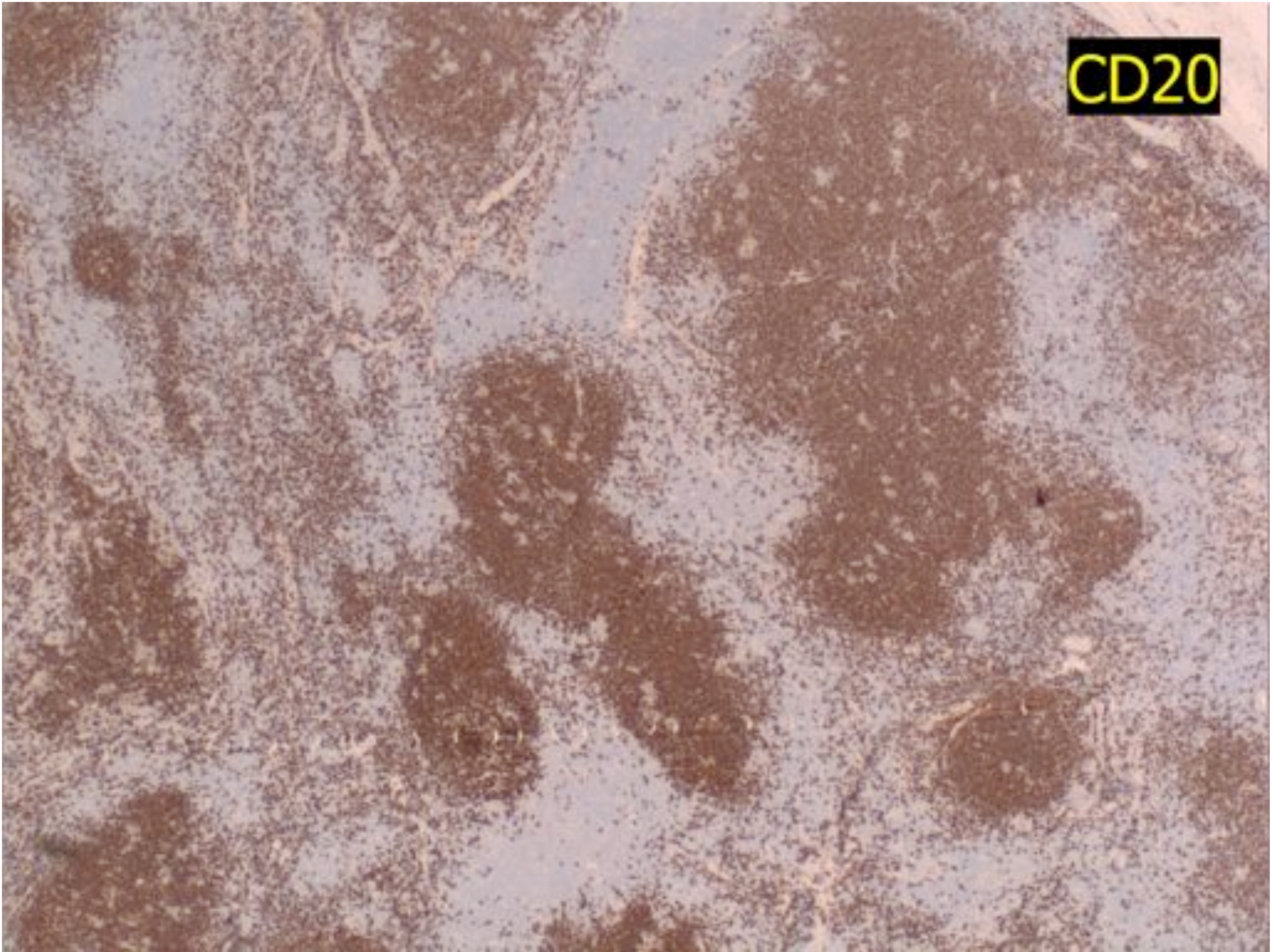




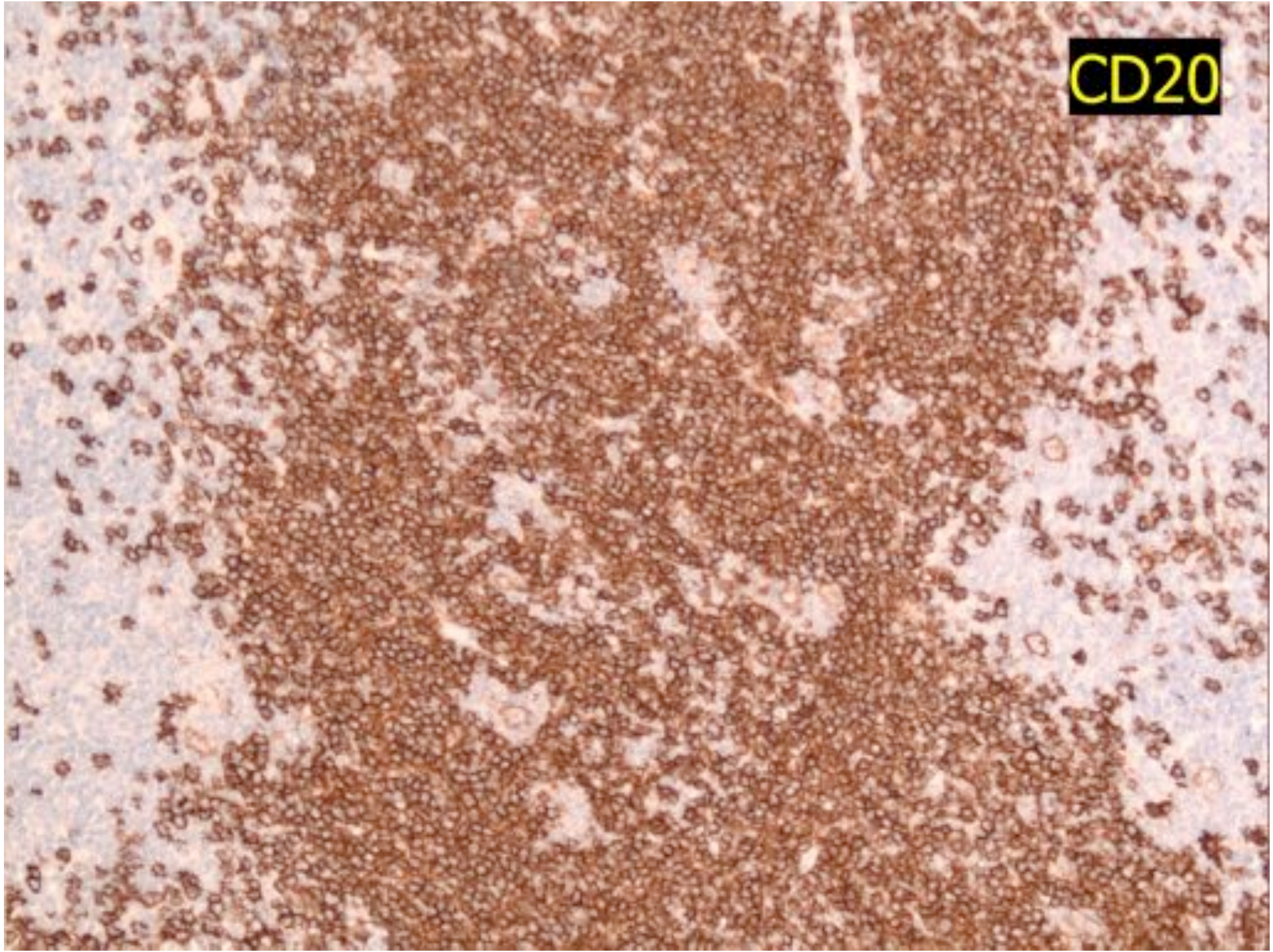
Popcorn (L&H cells)

- CD20 + and CD79a +
- CD45 +
- EMA + (50% of cases)
- CD15 neg
- CD30 neg

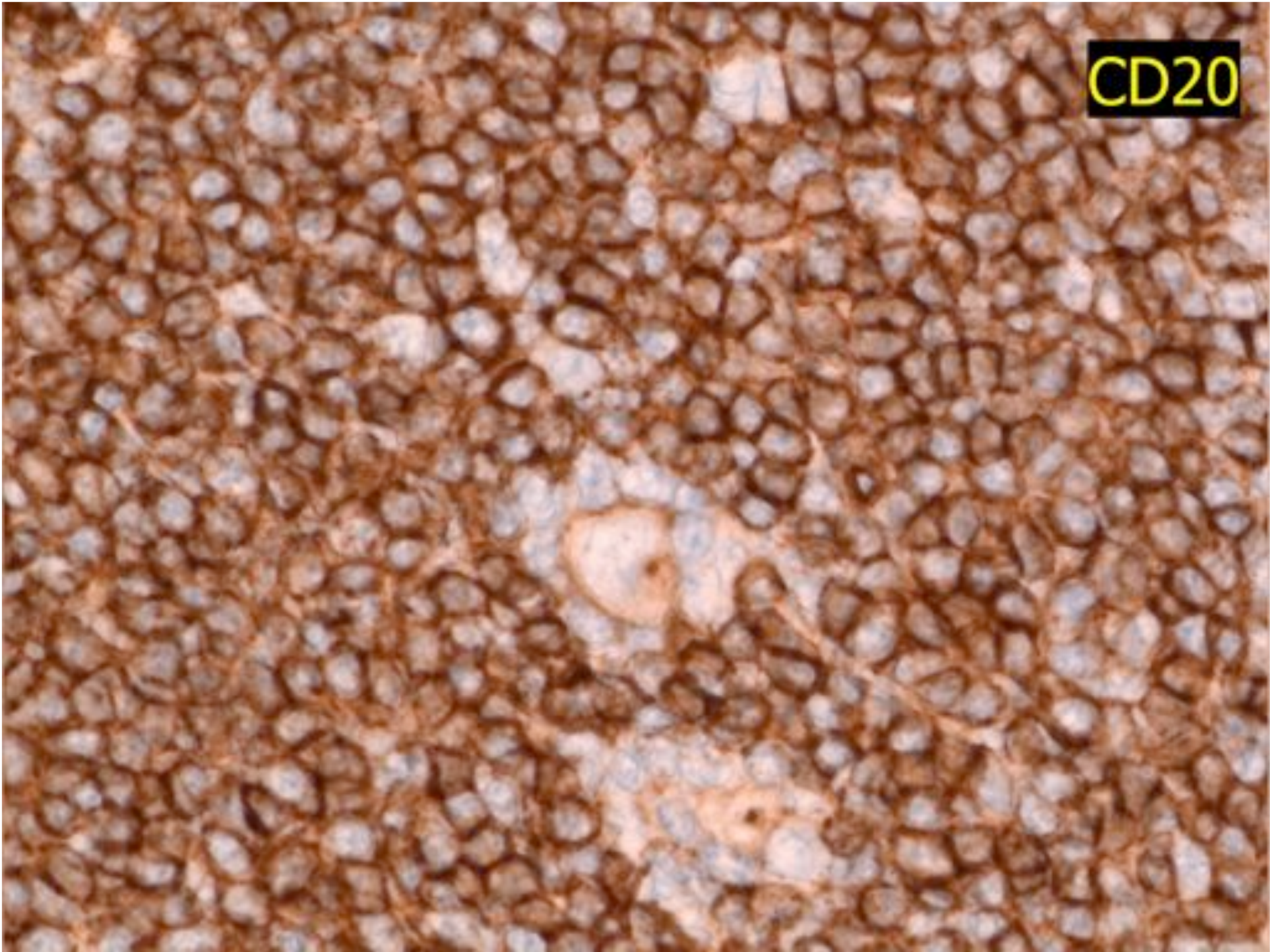
CD20



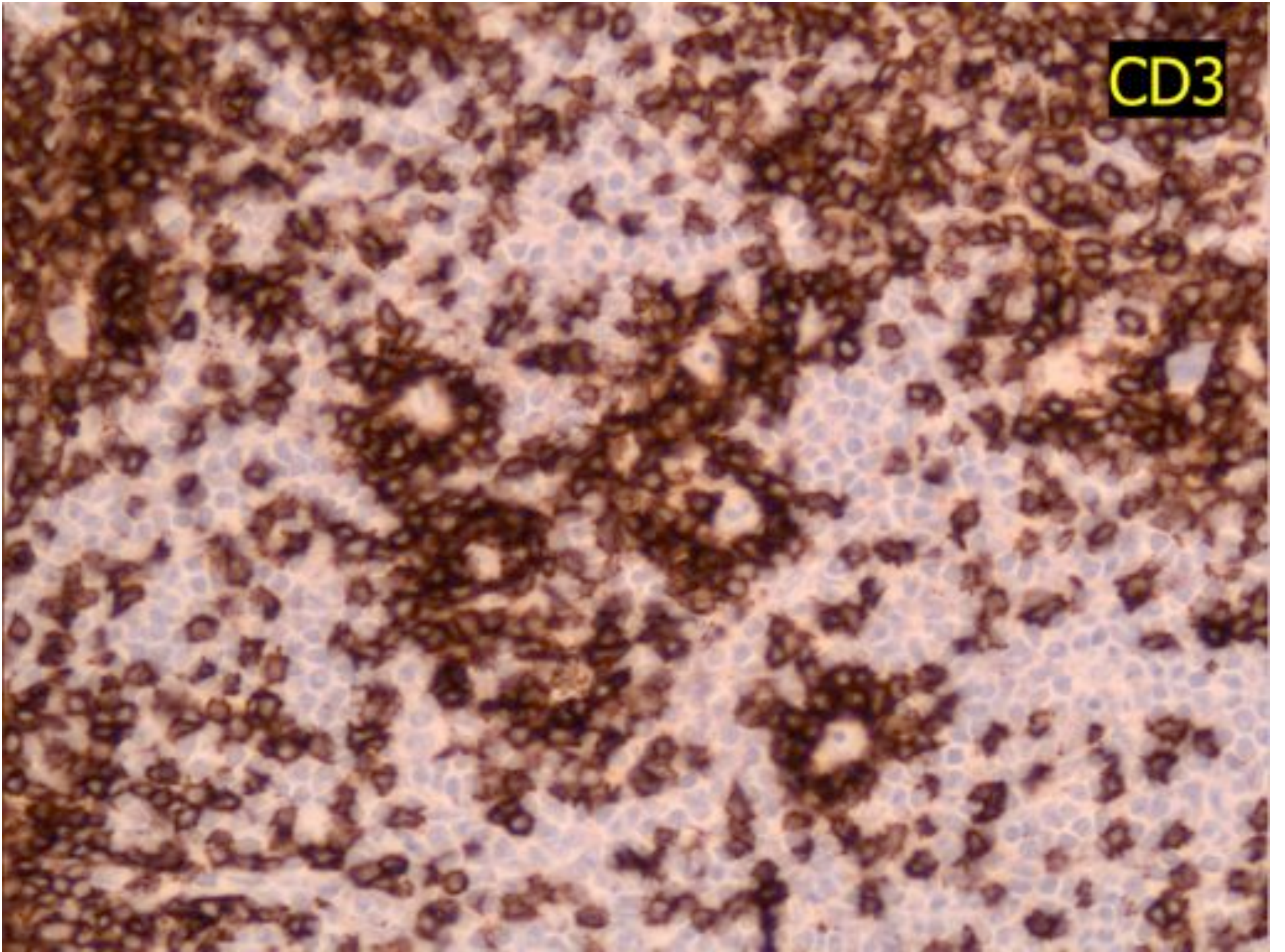
CD20



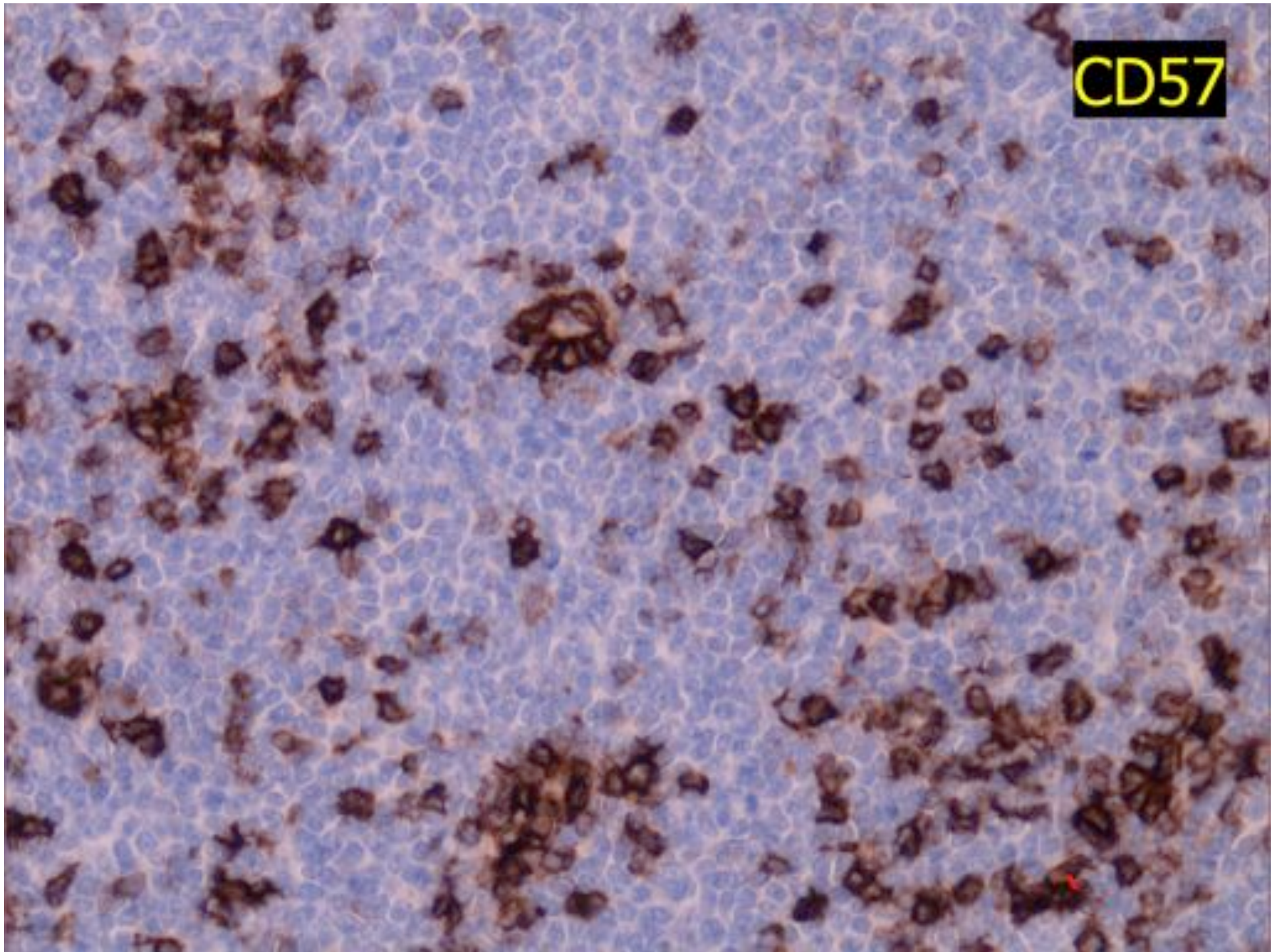
CD20



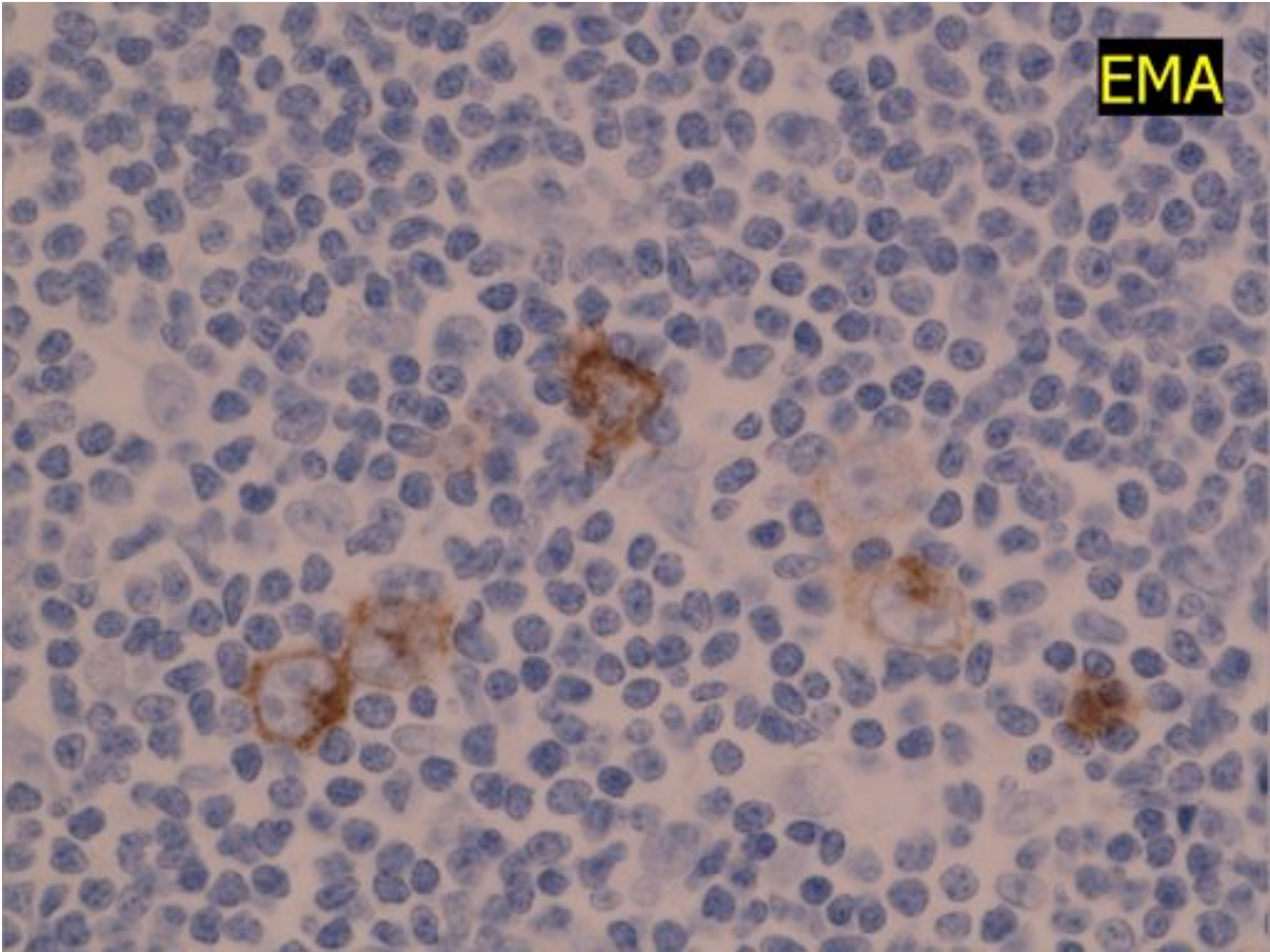
CD3



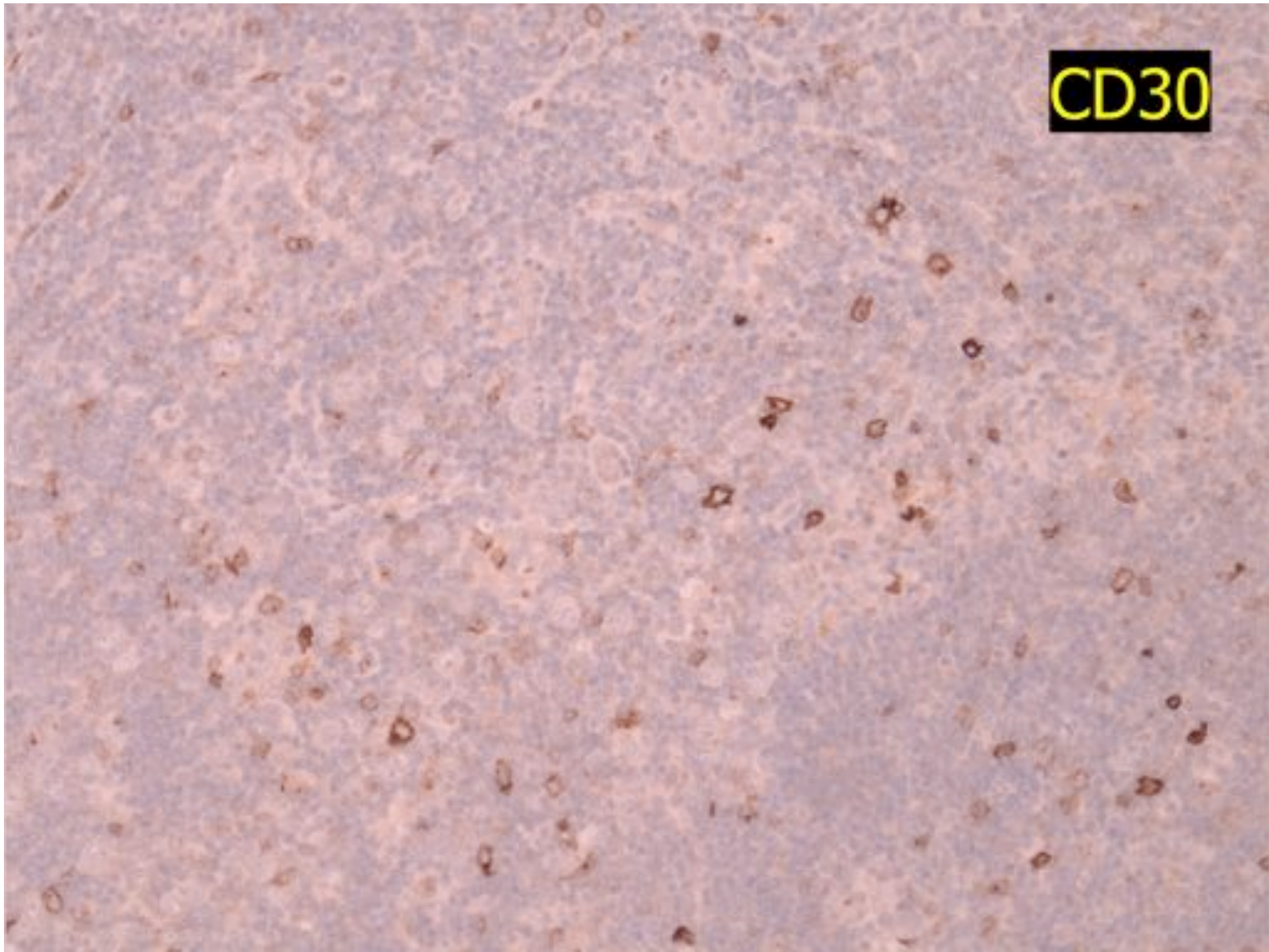
CD57



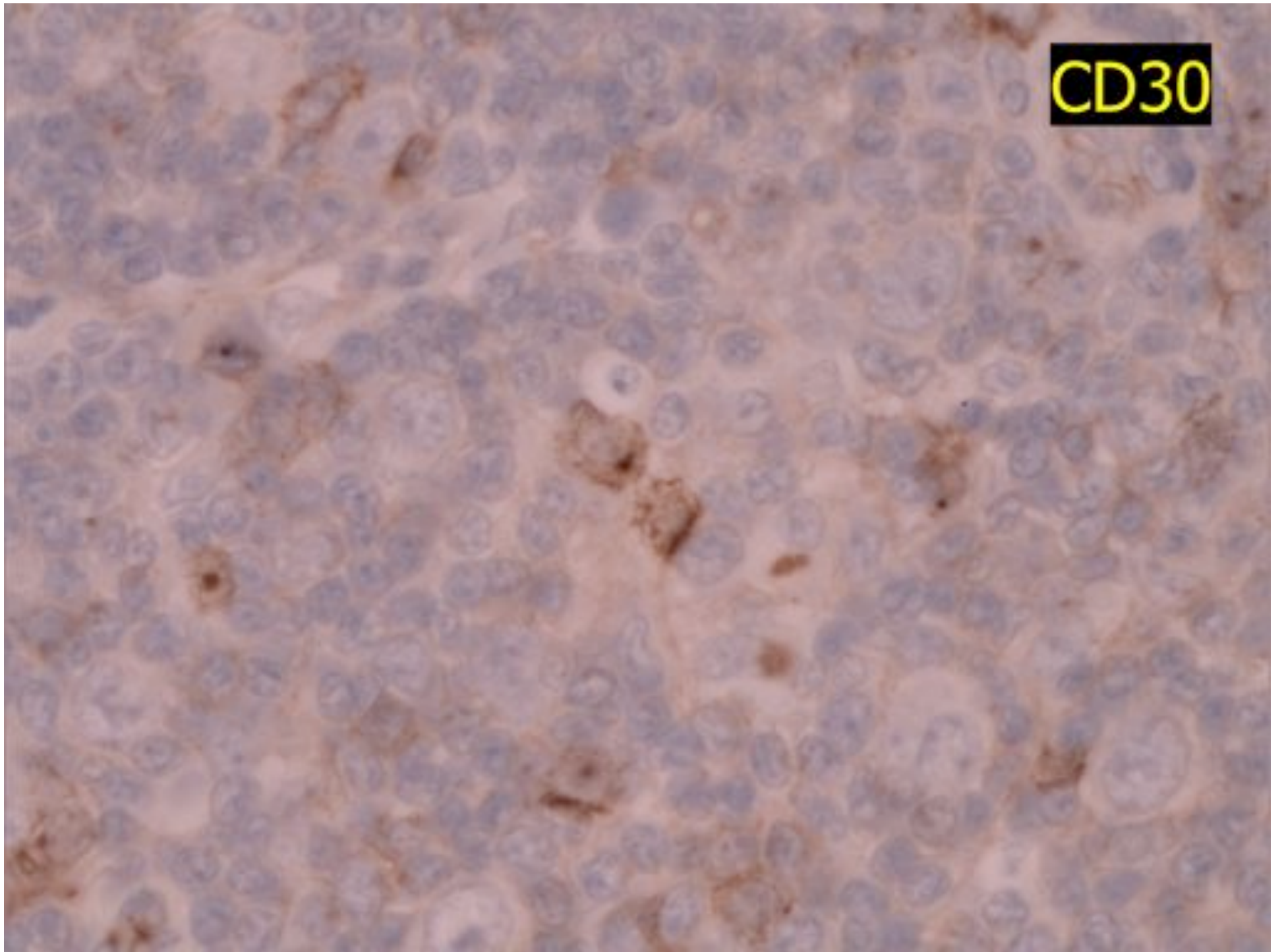
EMA



CD30



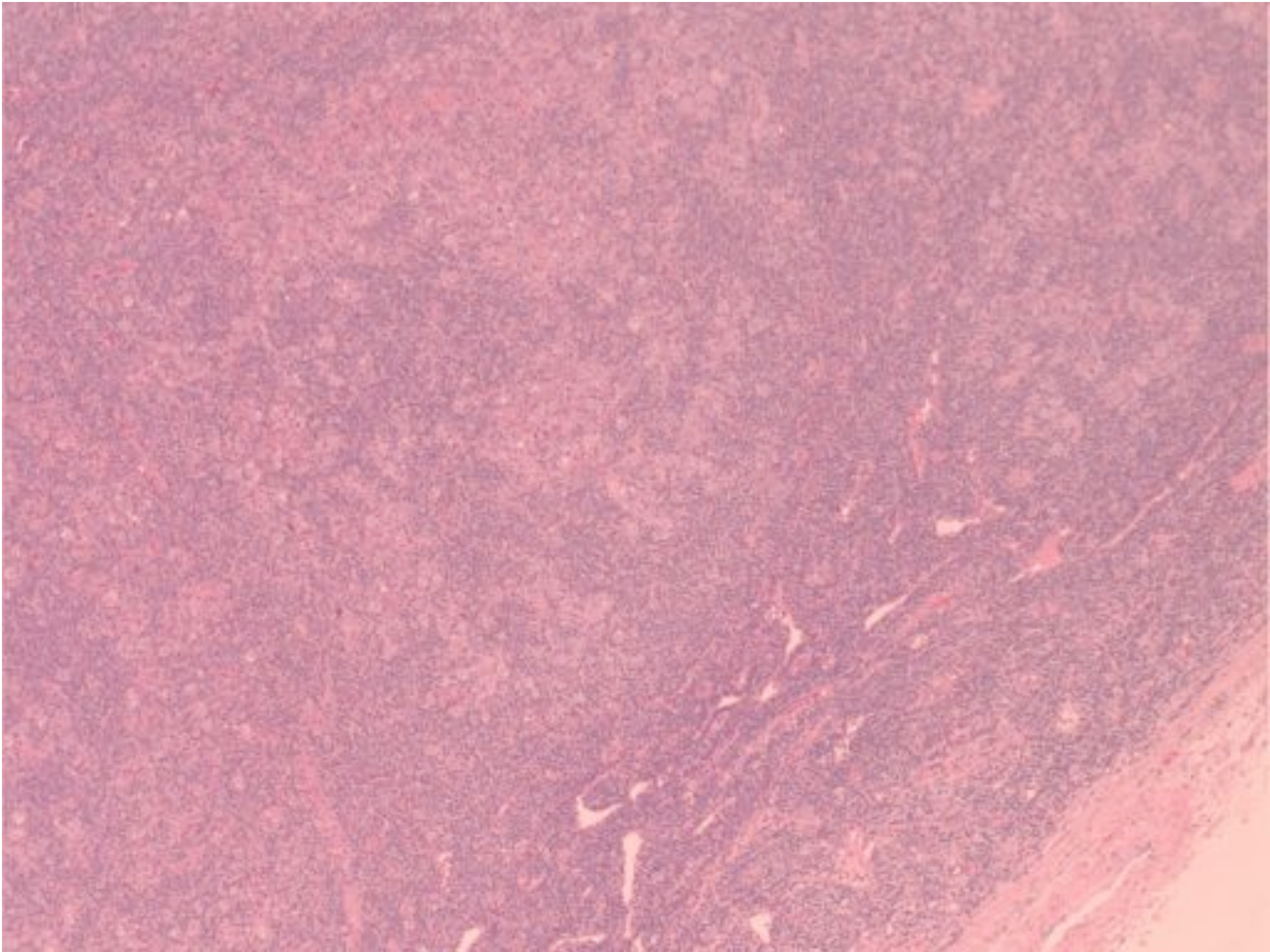
CD30

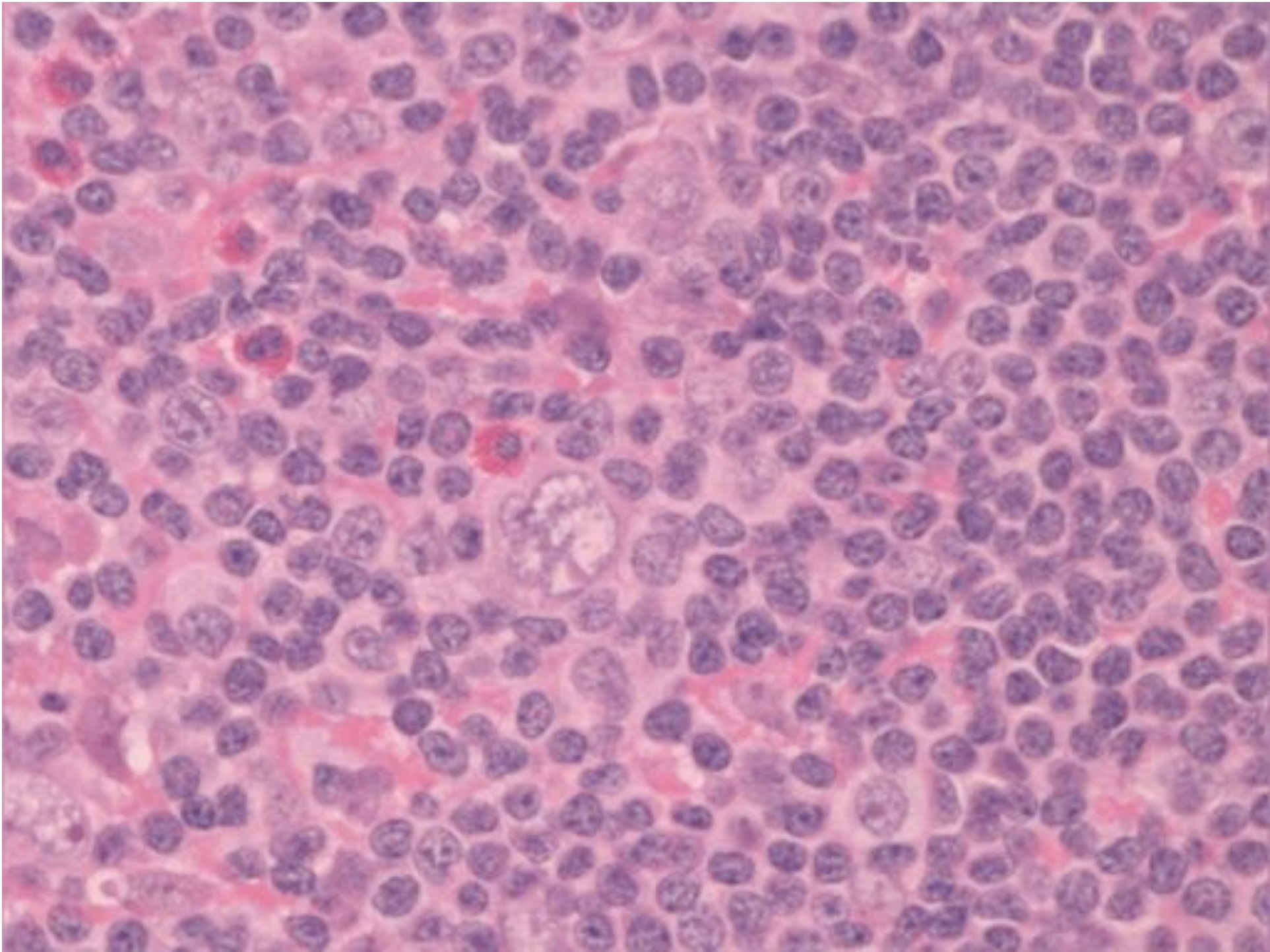


NLPHL

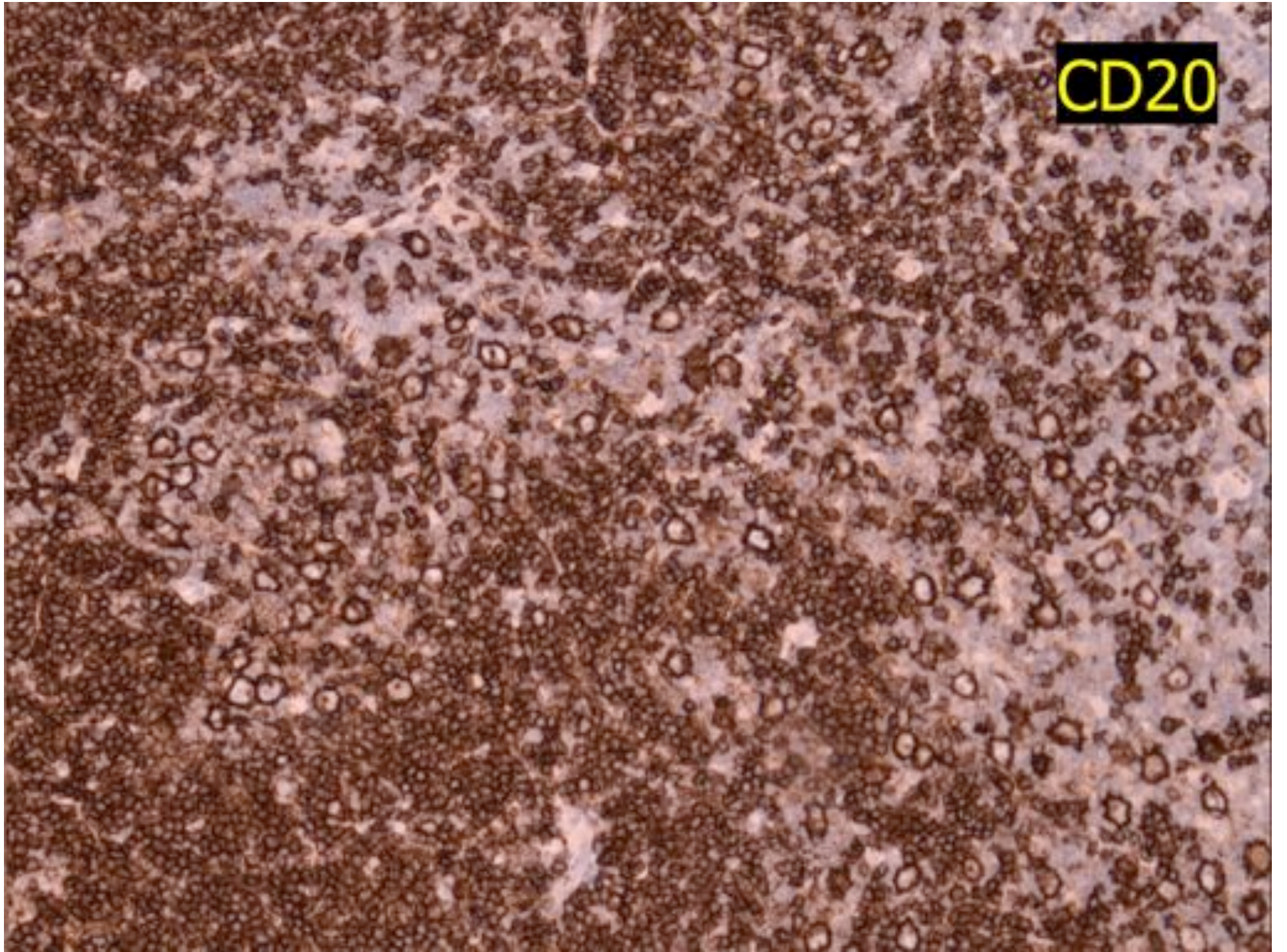
Disease progression

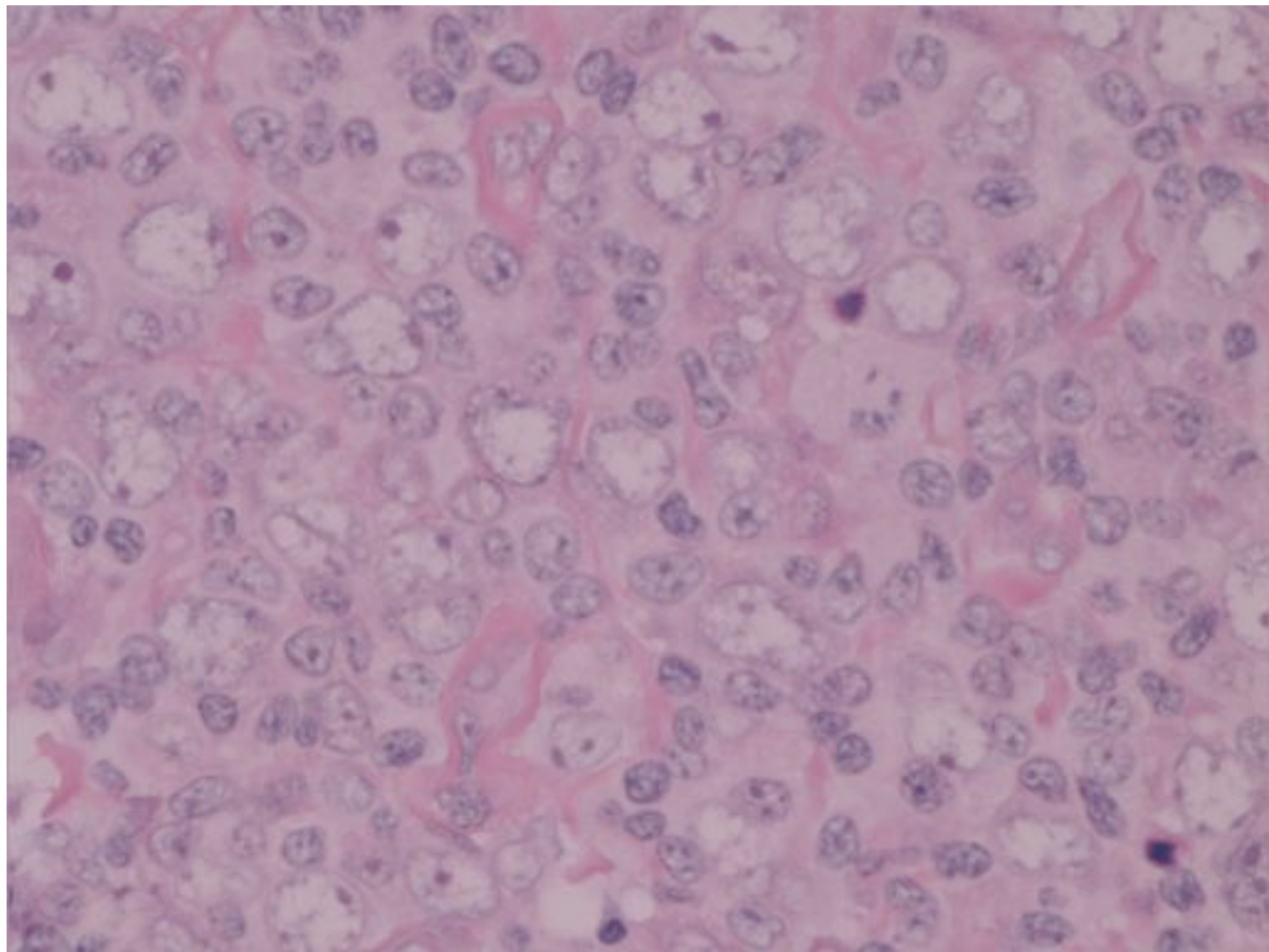
- Diffuse growth pattern
- Diffuse large B-cell lymphoma





CD20



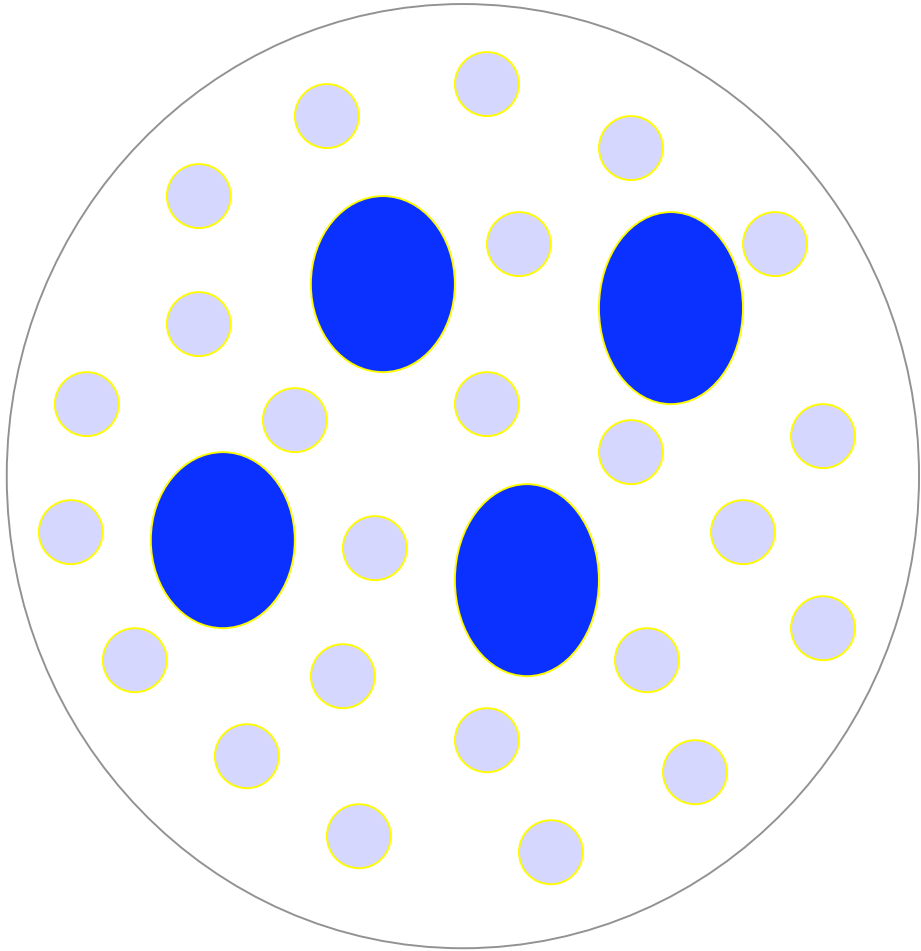


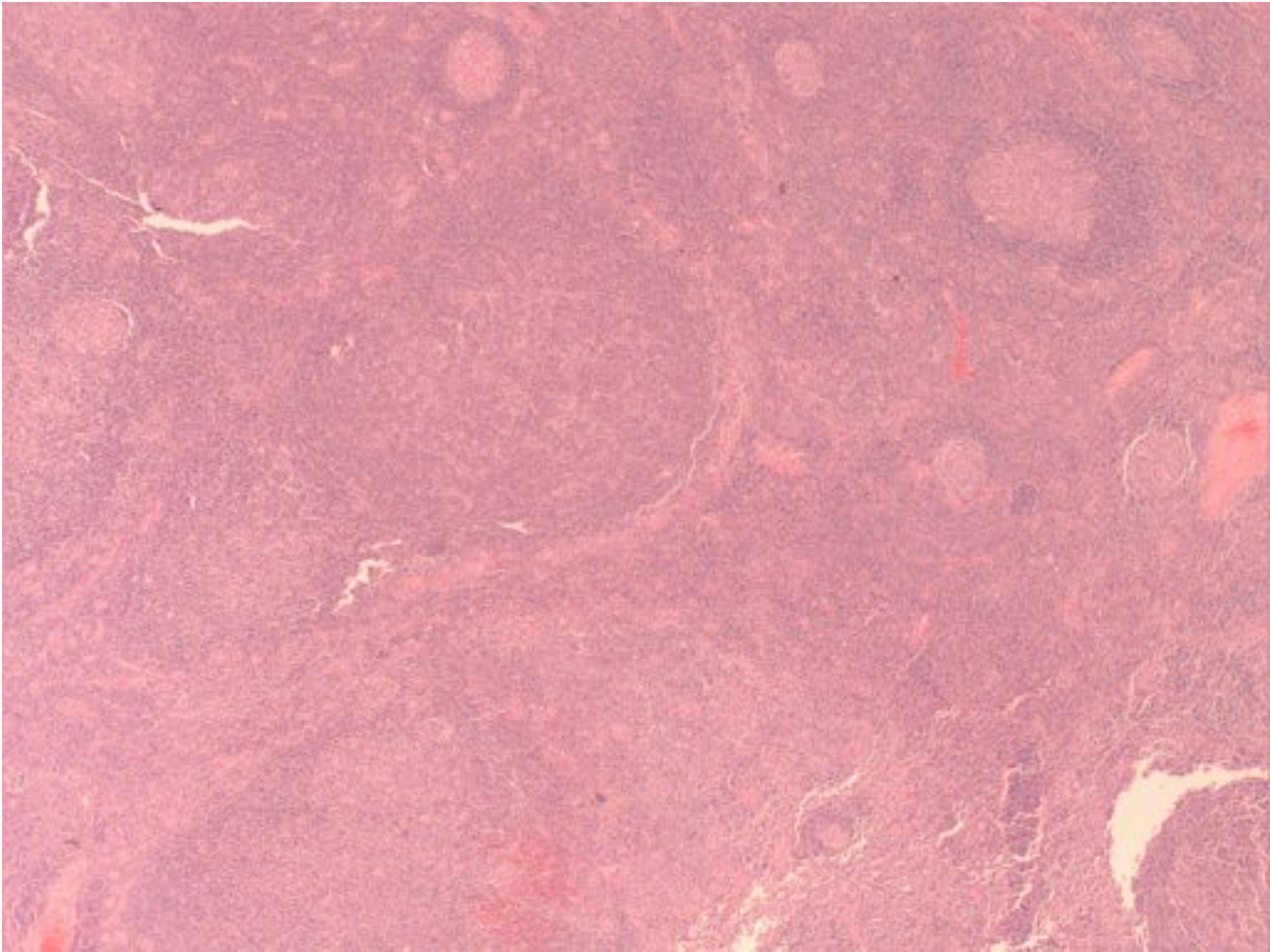
NLPHL Differential

- Nodular – PTGC
- Nodular – LRHL
- Diffuse – TCRBCL and diffuse LRHL

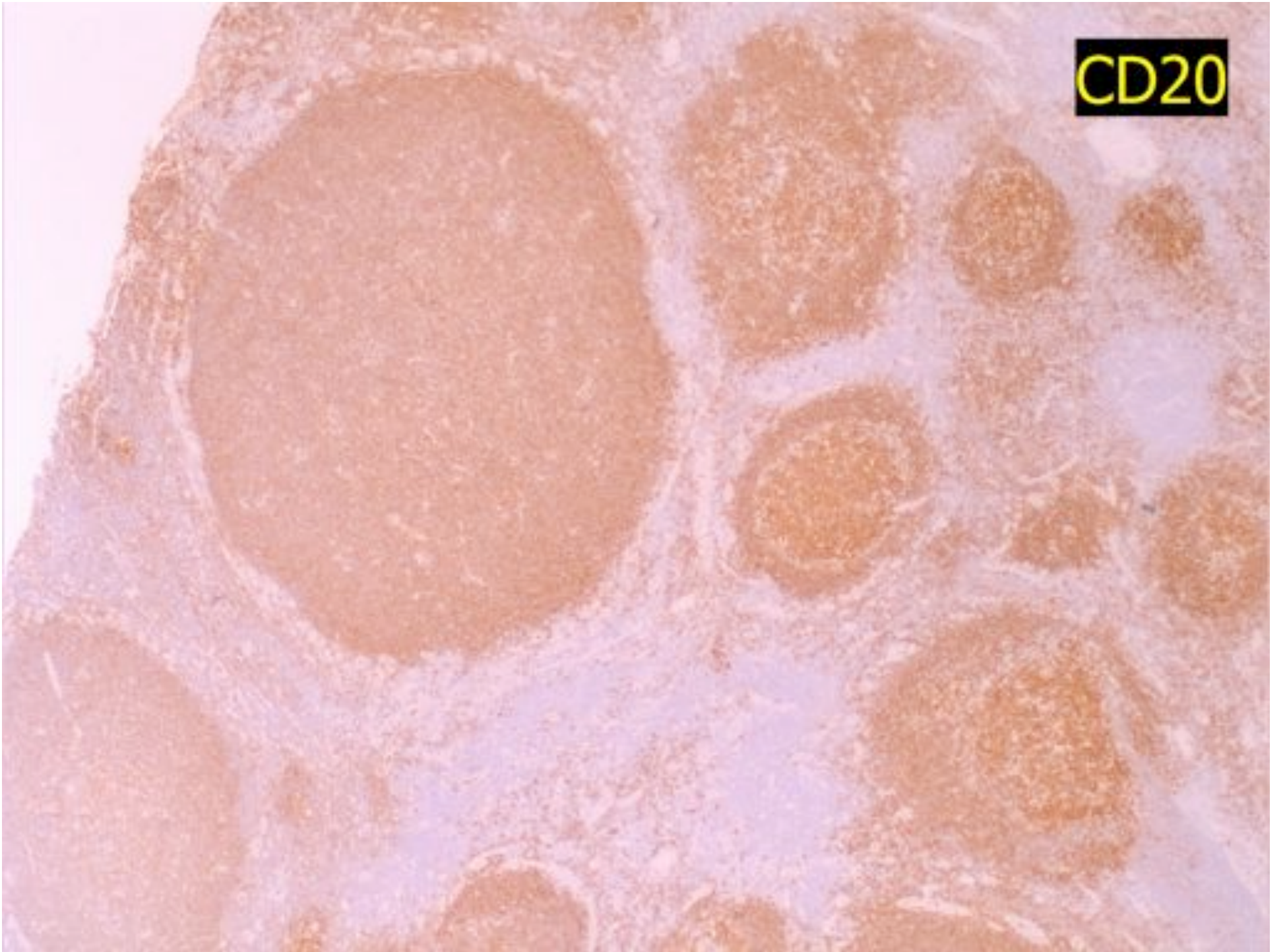
Progressive transformation of germinal centres

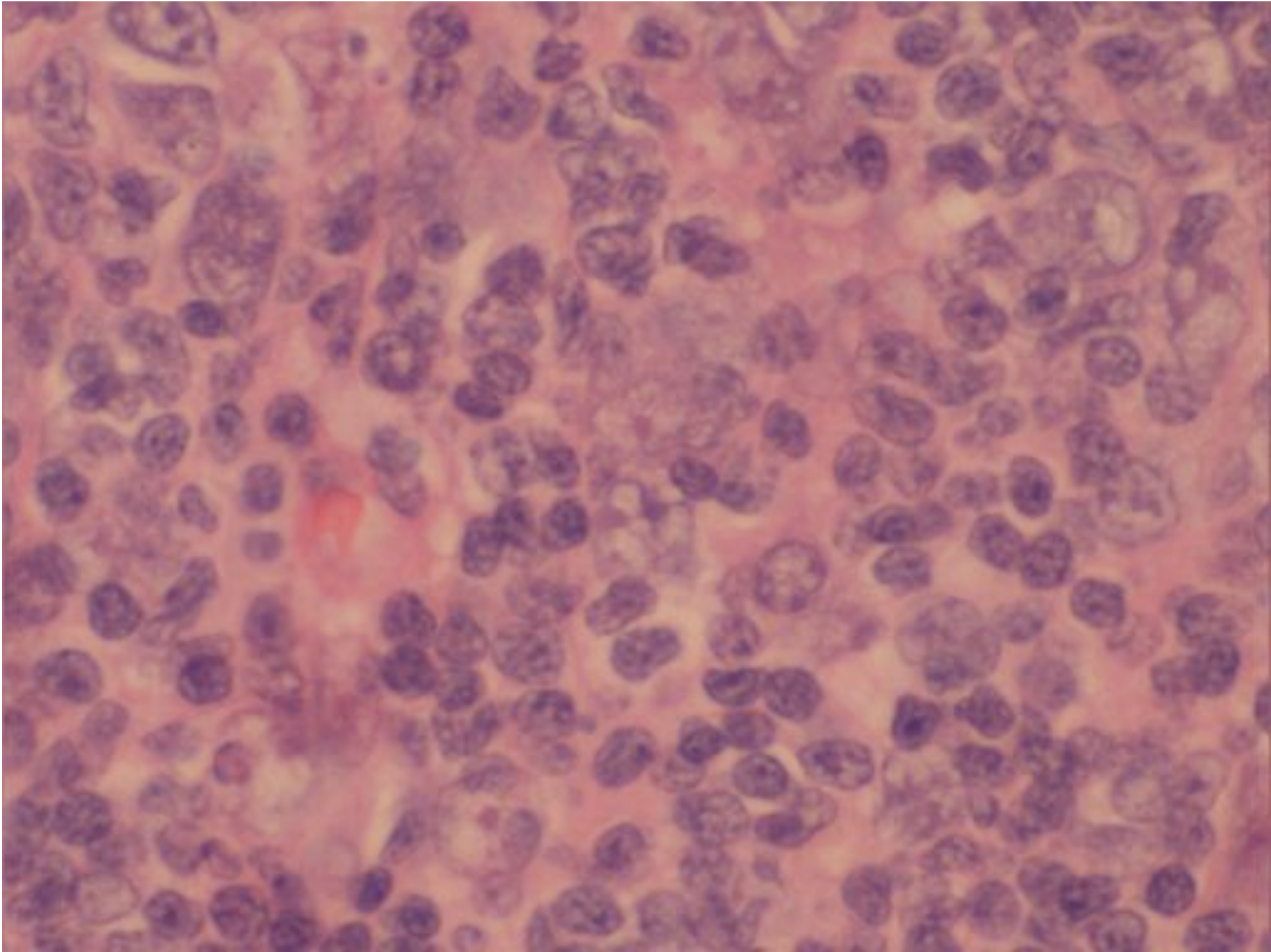
PTGC



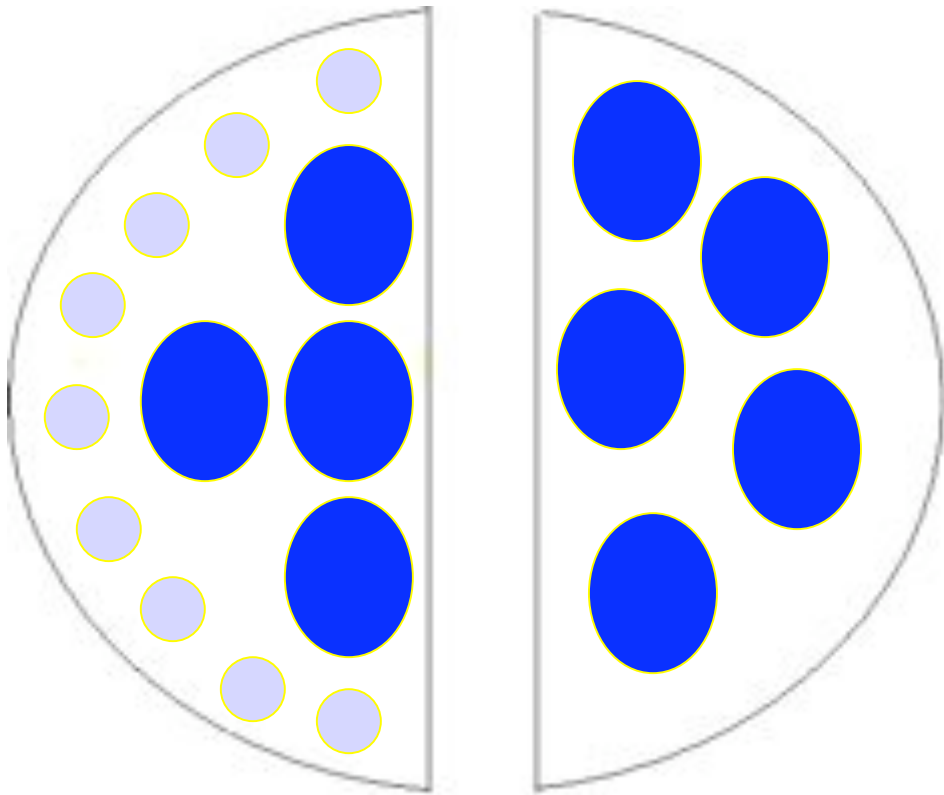


CD20

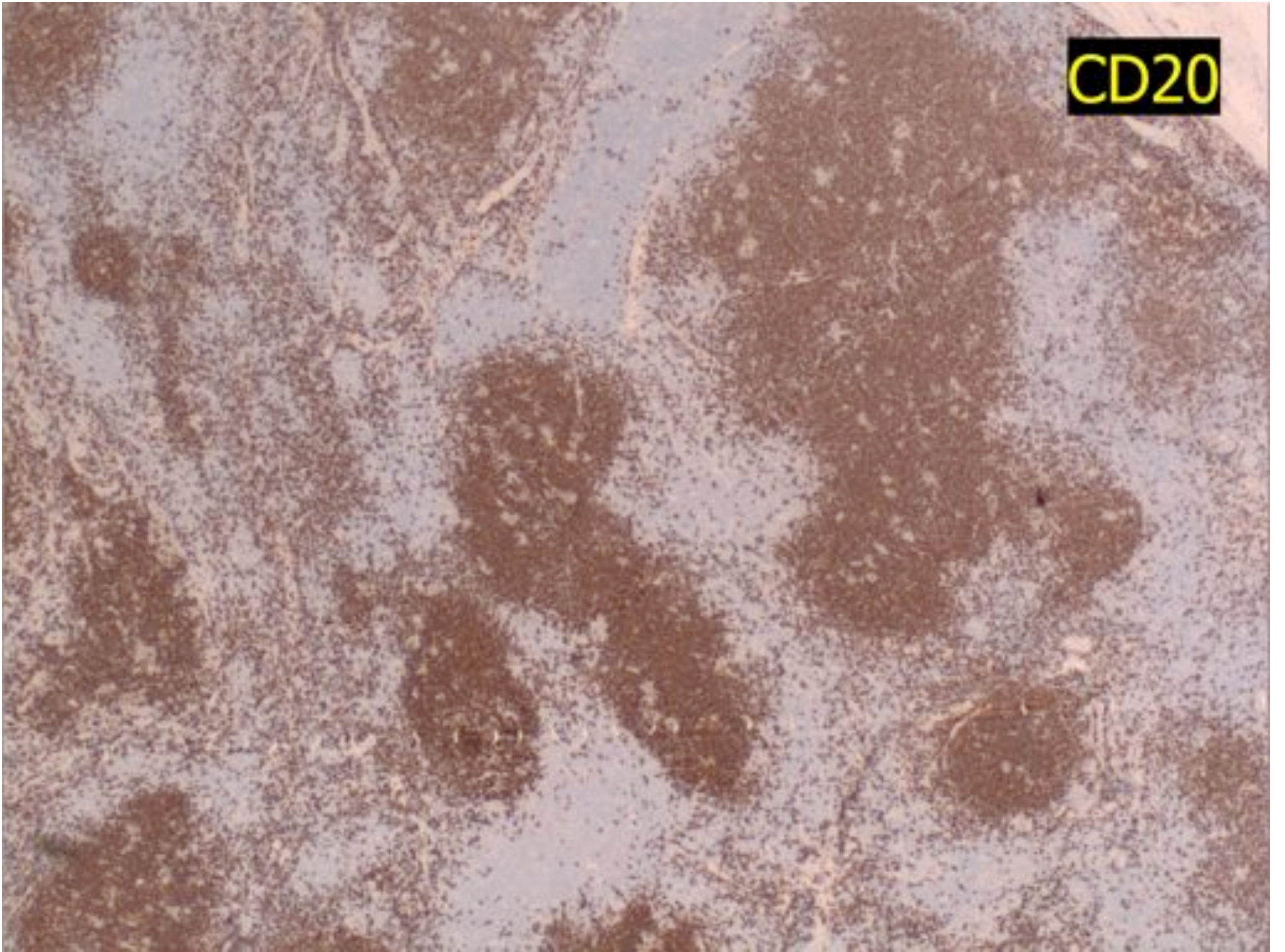


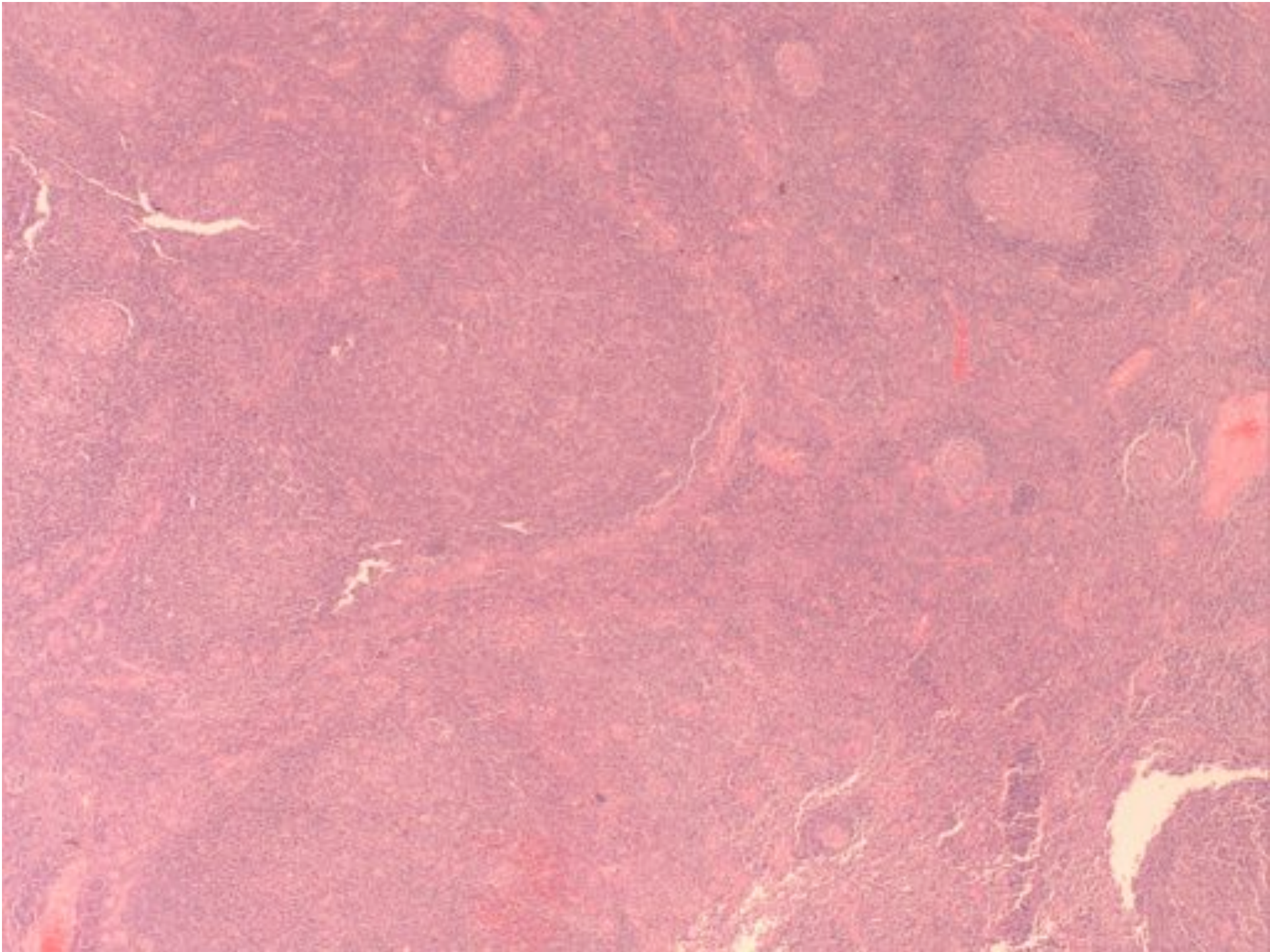


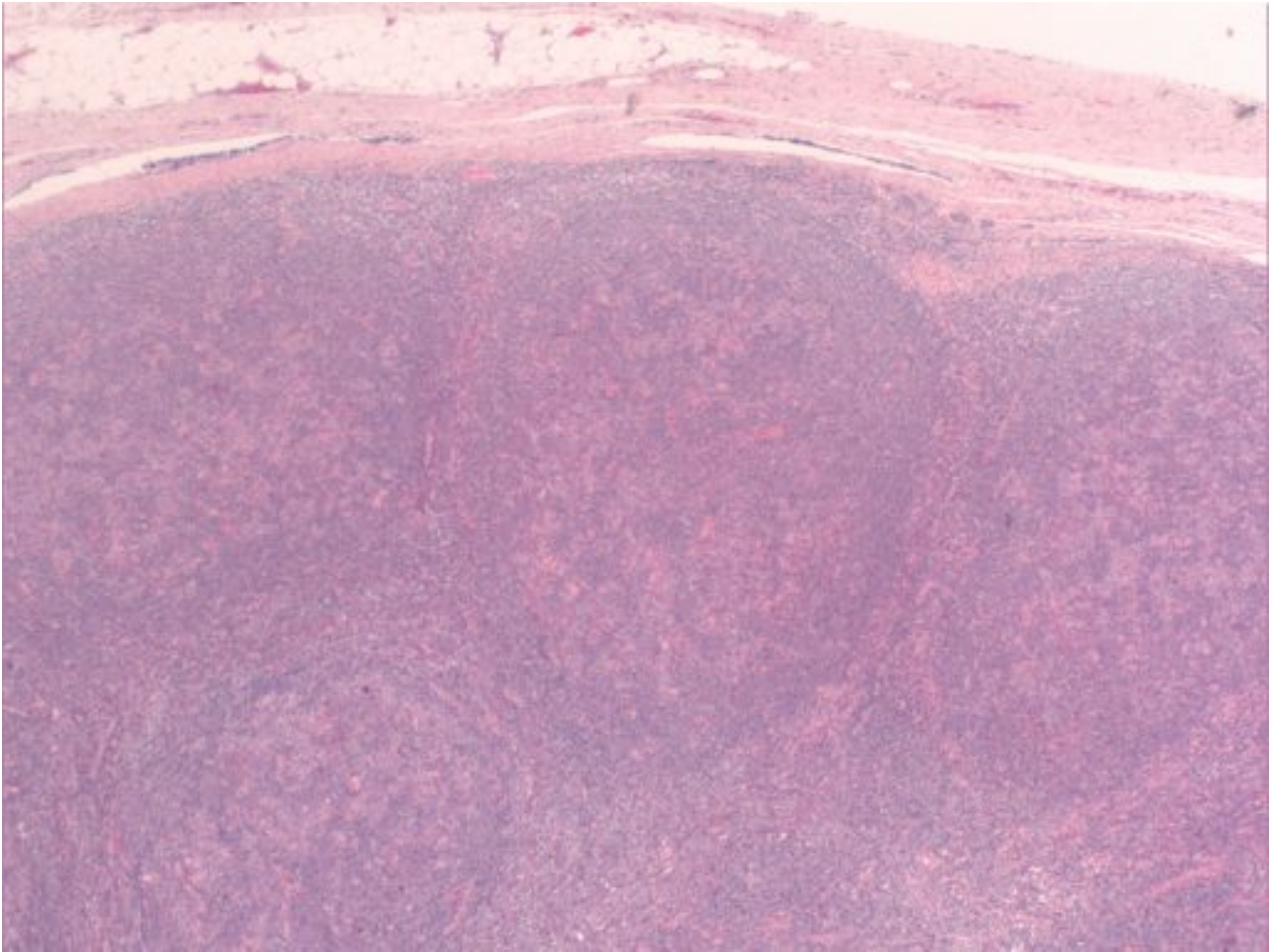
NLPHL



CD20



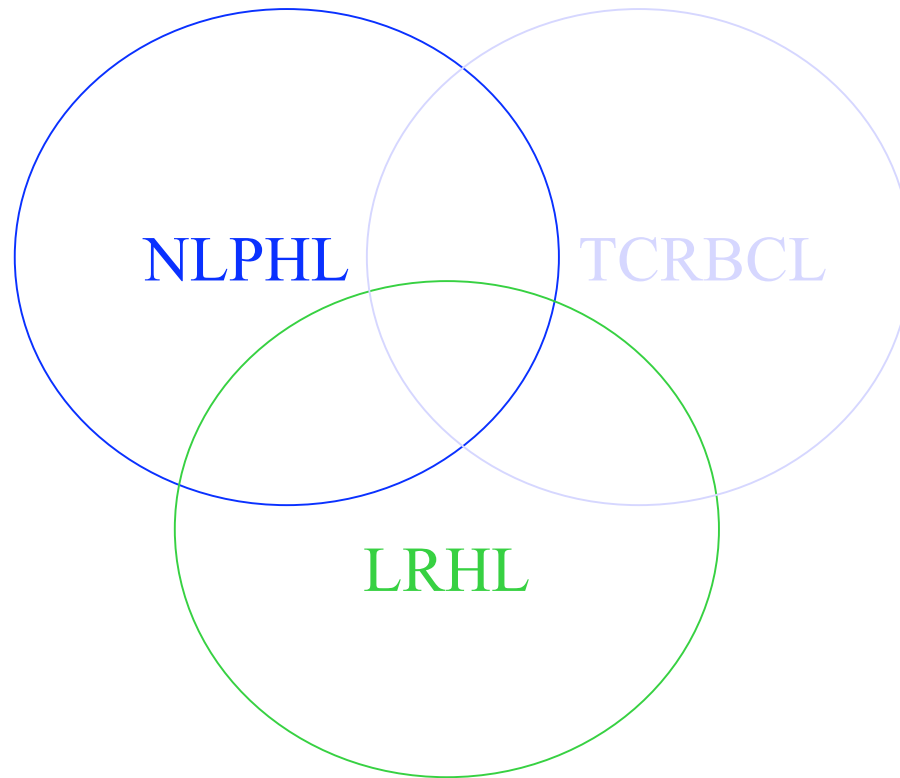




NLPHL vs LRHL

- LRHL
 - Classic HRS cells
 - CD15/CD30 positive
 - B-cell markers negative

DIFFUSE



HODGKIN LYMPHOMA